



Attempting Heroics: Restoring Buccally Angulated Implants

Ryan Leong D24284

Patient Info

Mona, 40 year old Female

CC: I want to get implants for all my missing teeth

HCC: Got upper left implants placed in 9/2022

DH: moderately restored with previous RCT and EXT

SH: Lives in Los Banos (minimum 4 hour drive round trip), currently working and can now only come in on Thursdays, -EtOH, -TOB, -IVD, -MJ

Medical History



Vitals and Incidents

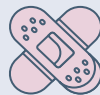BP: 131/92 mmHg
HR: 101 bpm

Car crash in 2003
Constant migraines



Medications

Topamax PRN
Excedrin PRN
Ibuprofen PRN
Gabapentin 300mg TID



Allergies

Penicillin



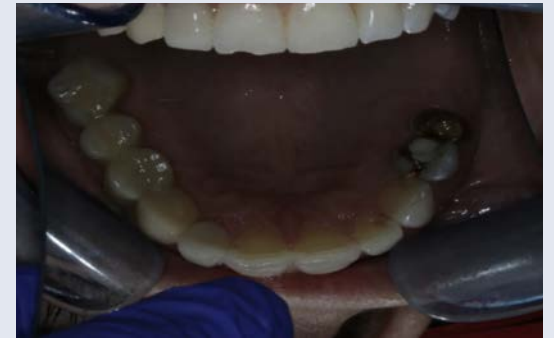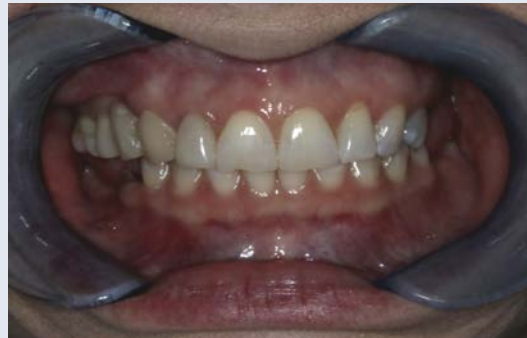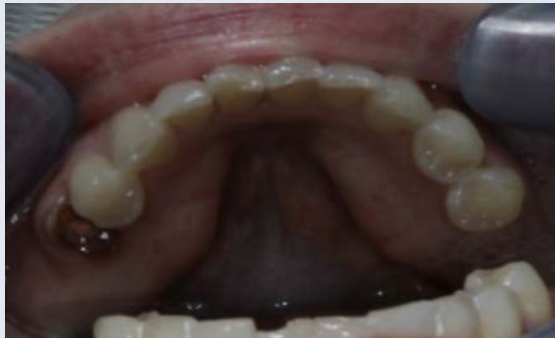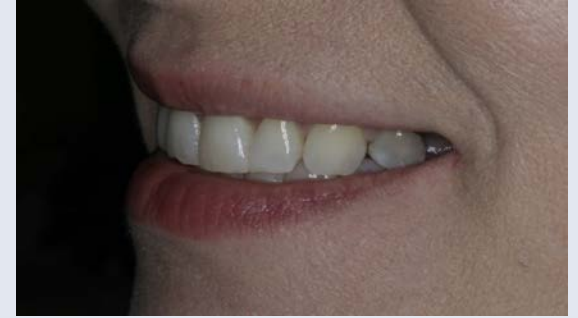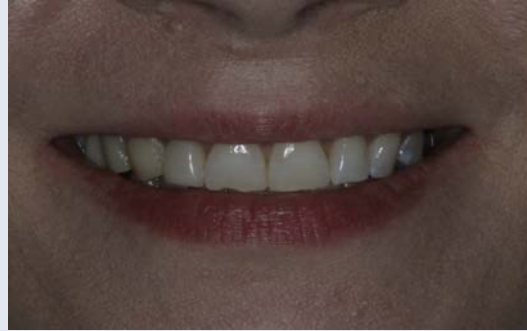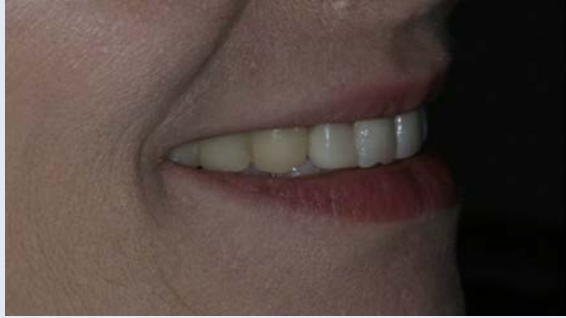Previous Operations

Nerve ablation
surgery 7/2022

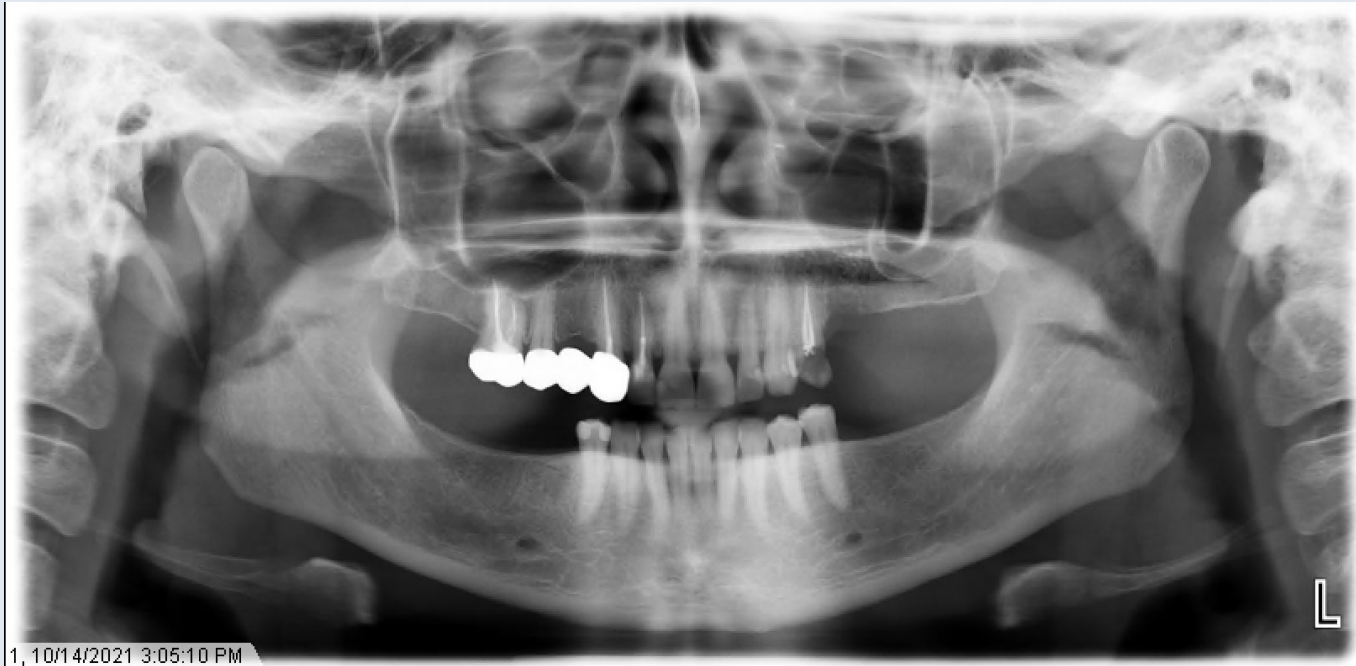
Laparoscopic
bilateral hernia
surgery 2/2023

Splenectomy as a
teen

Patient Photos



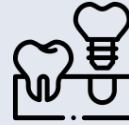
Panoramic



Treatment Plan

1. Urgent
2. Disease
 - a. Prophylaxis
3. Restorative/Reconstructive
 - a. #12, #14 Surg. Implant placement
 - b. #8 IFL
 - c. #9 IFL
 - d. #25 IFL
 - e. #12-14 PFM Implant Bridge
 - f. #19 Surg. Implant placement
 - g. #19 Zirconia Implant crown
 - h. #29, #30 Surg Implant placement
 - i. #29, #30 Zirconia Implant crowns
4. Maintenance
 - a. Lower RPD adjustments/recalls
 - b. 6 month prophylaxis

#12-14 Implant Placement



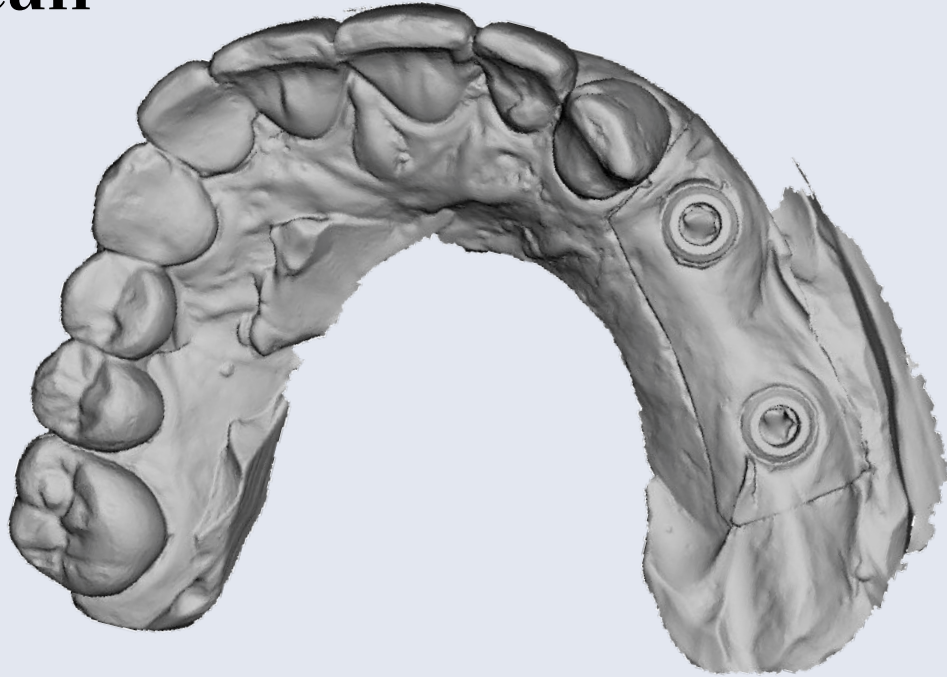
Implants placed on 9/9/2022

No Surgical Guide used

#12: TLX Straumann 3.75mm x 10mm

#14: TLX Straumann 4.5mm x 10mm

Model Scan



Notice how buccal the implants are placed

#12-#14 Bridge Restorative Plan

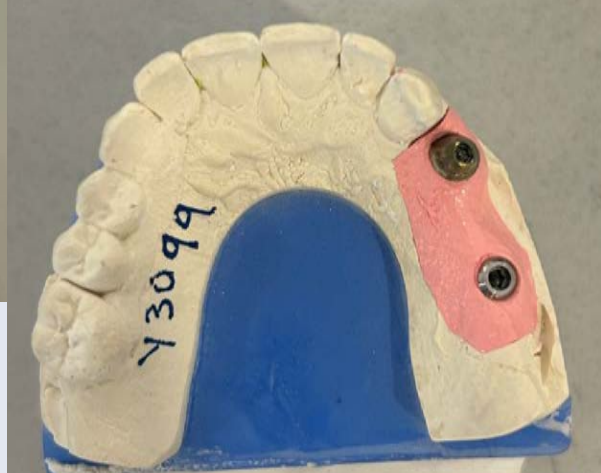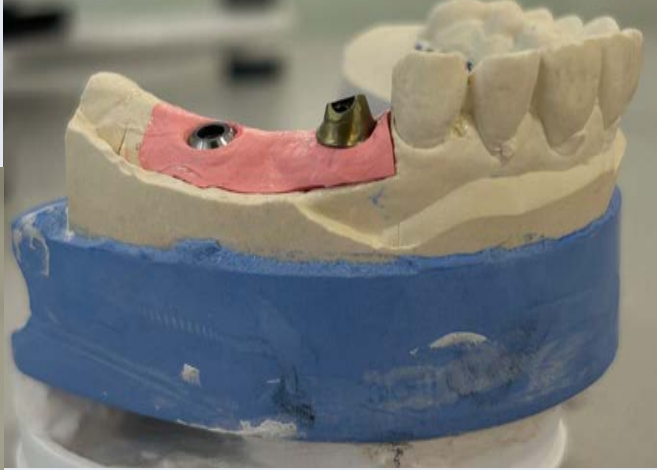
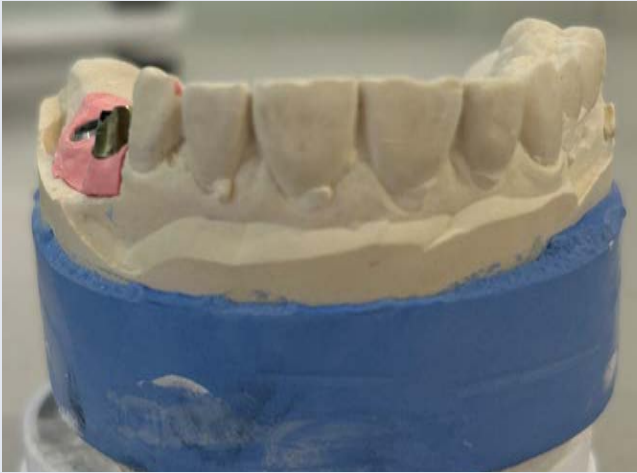Due to placement and angulation of #12 implant, #12 is cement retained¹ and #14 is screw retained.

But wouldn't that make the bridge unretrievable???

If we were to use permanent cement, then yes; however using a temporary cement such as TempBond allows us to cement the crown while also making it retrievable.

1. Choy K, Sattler D, Daubert D, Wang IC. The effect of cement versus screw-retained implant positioning in the esthetic zone on emergence angle: A proof of principle. Int J Periodontics Restorative Dent. 2023 Oct 11;0(0). doi: 10.11607/prd.6903. Epub ahead of print. PMID: 37819846.

#12 Custom Abutment

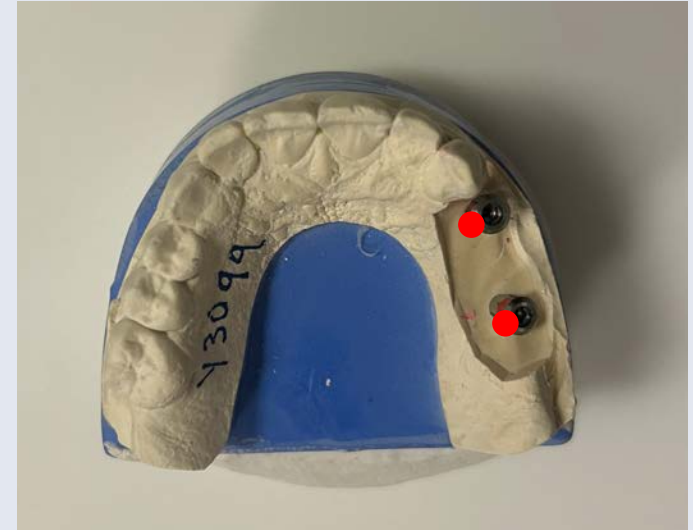


CIMOE Attempt #1 (5/25/23)

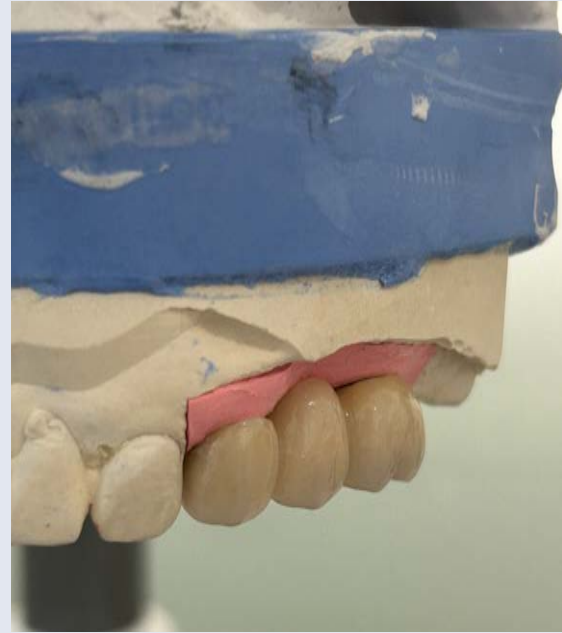

Issues:

- No occlusion
- Metal abutment platform showing at gumline
- Not passively fitting
- Buccal too bulky
- It became evident that the buccal angulation of the implants was going to be a problem

Verification Jig was created and confirmed that the implants intraorally and on the master cast analogs were identically positioned.



Master Cast



Margin appears hidden on the model

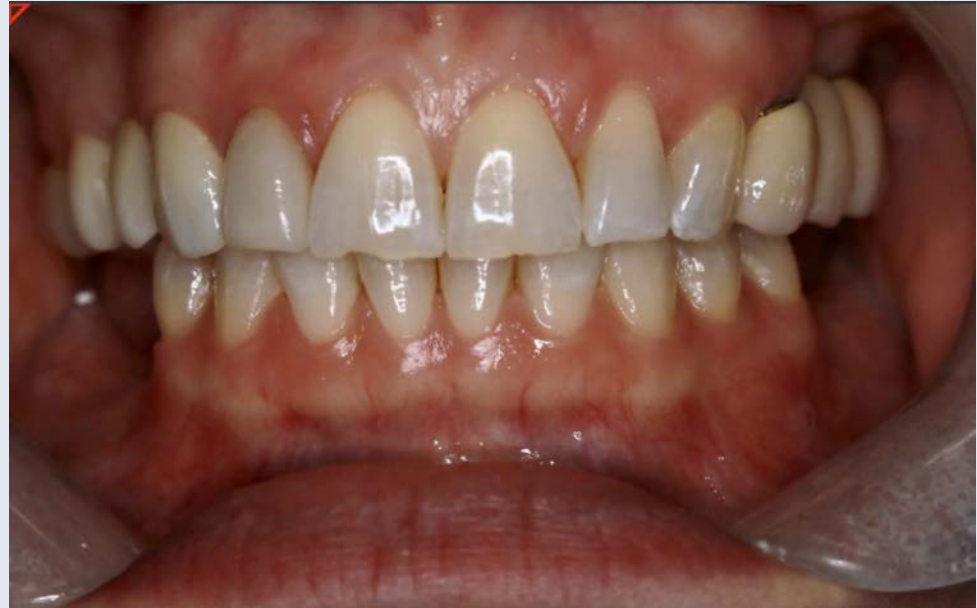CIMOE Attempt #2 (8/3/23)

Issues:

- Buccal too bulky
- Metal showing at the gingival margin
- Shade too dark
- Path of insertion
- “Looks the same as last time”

Result of the appointment:

- Retake impression with a new verification jig
- Select new shade



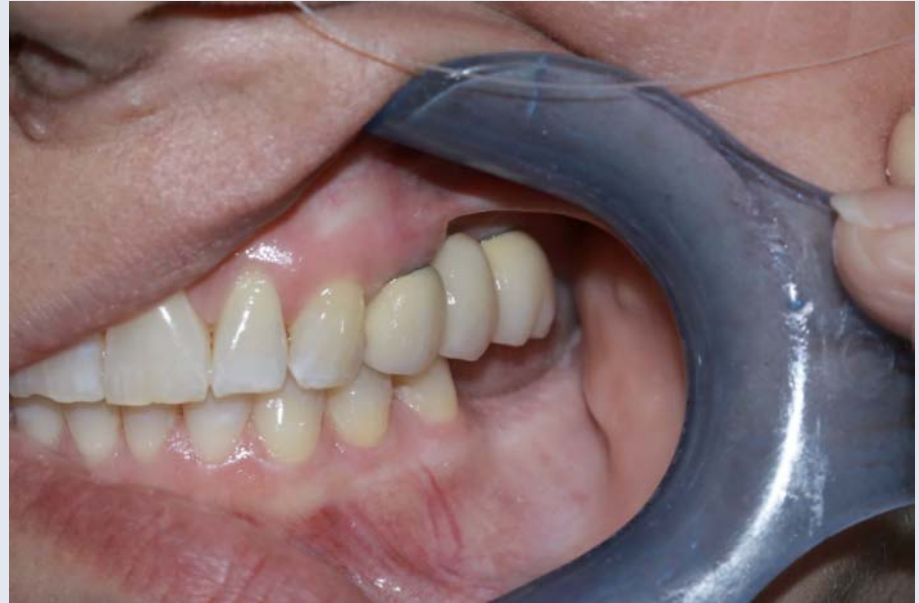CIMOE Attempt #3 (9/14/23)

Issues:

- Metal margin still showing, but improved
- Shade better, but still too yellow for patient's liking
- Still too bulky on buccal

Result of the appointment:

- Take another impression to recapture soft tissue
- Make shade lighter
- Come up with a new restorative plan

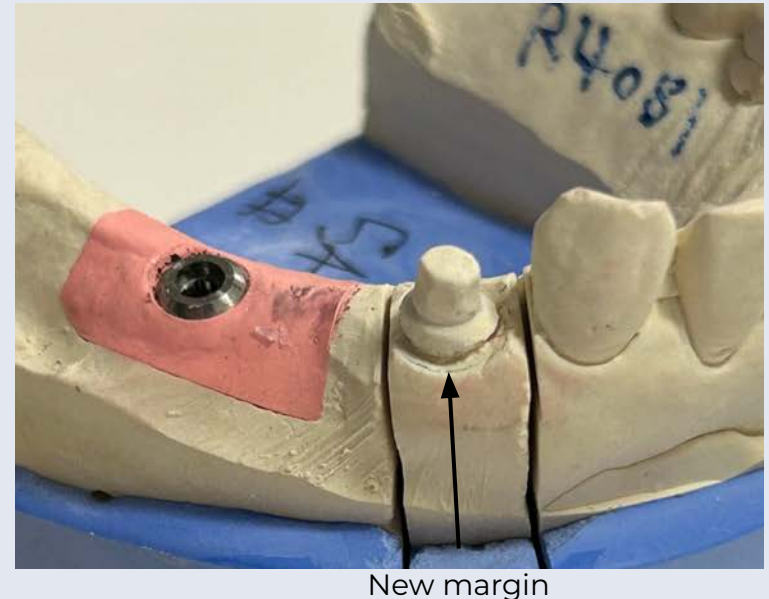
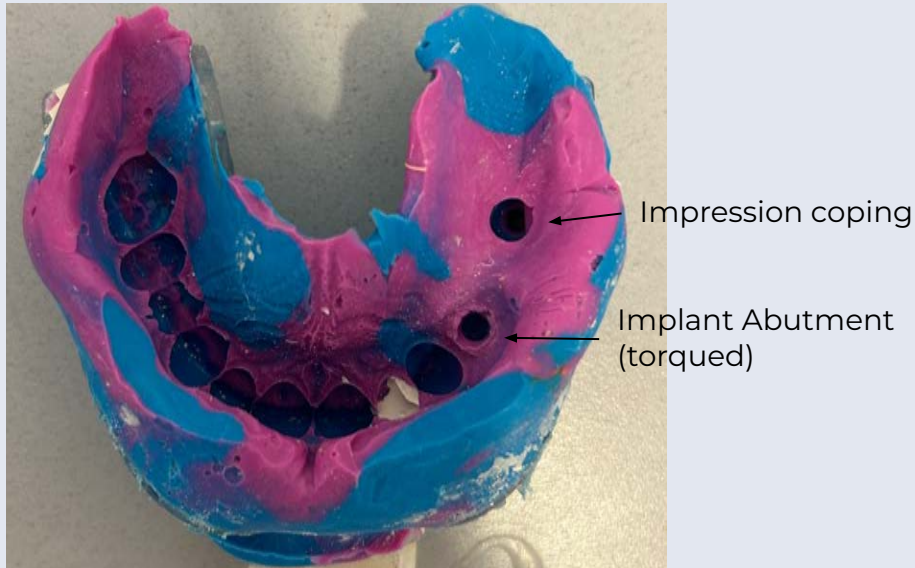


What are our options now?

1. Connective tissue graft to better cover the implant at the margin
2. Tell the patient this is the best we're going to get with the case we were provided due to placement by the surgeon
3. Improvise and come up with something unorthodox

Something unorthodox... (11/9/23)

In order to move the margin gingivally, a stock abutment and the implant body were prepped with a crown bur, creating a margin in which a “normal” crown can be fabricated on top of.



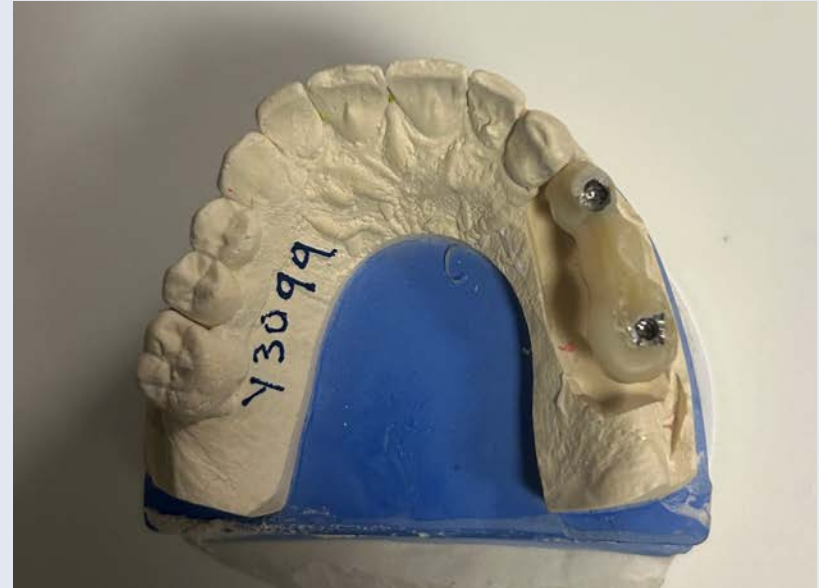CIMOE Attempt #4 (2/16/24)

Issues:

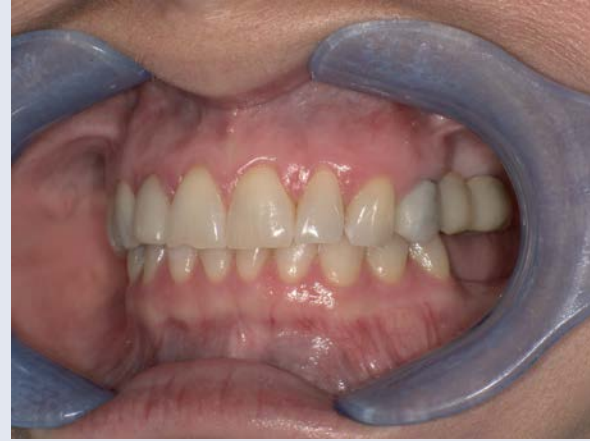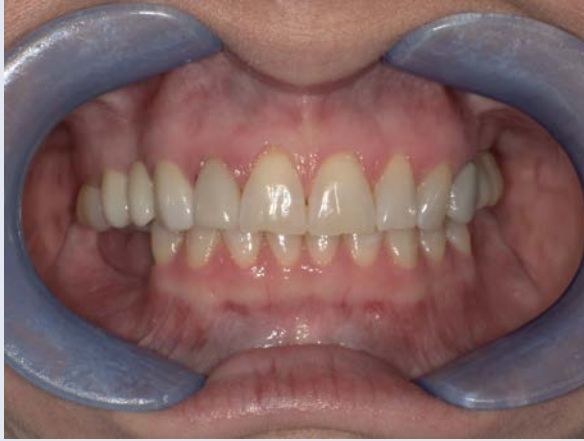- Metal Margin still showing
- Still too bulky on buccal
- Shade too light for patient's liking

Result of the appointment:

- Temporary bridge fabricated
- Shade adjusted again



Temporary Bridge



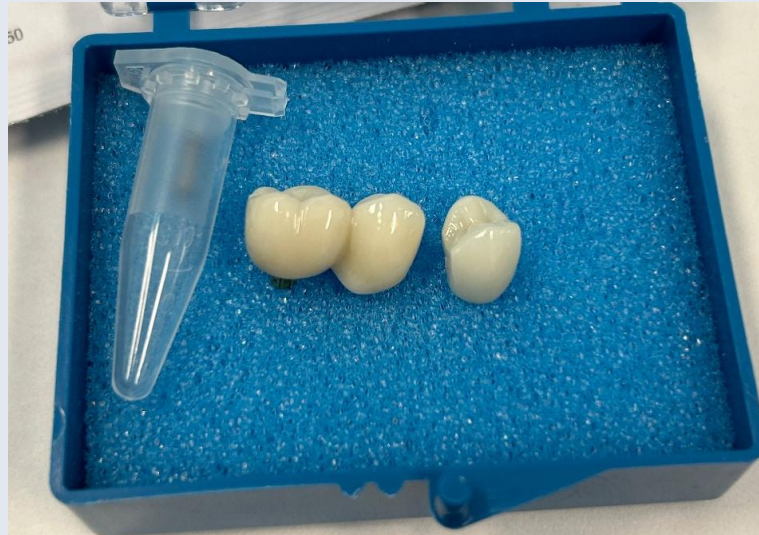Due to angle of the implant, the temporary abutment showed through the buccal integrity/composite on #12. The metal was reduced as much as possible without perforating into the screw channel.

Patient was happy to finally have some teeth on the left side and ended up getting engaged and married!

Ok... so now what?

It was suspected that the torquing of #14 was displacing #12, causing incorrect seating.

So we cut #12 off of the bridge, creating a mesial cantilever off of #14, and added porcelain to reestablish contact and to hide margin on #12



Why use a cantilever?

Premolar pontic off a molar implant

Implant Cantilevers have a 10 year survival rate of 88.9% to 100%⁴

No statistically significant difference in peri-implant bone levels between cantilevered and non-cantilevered implant prostheses^{3, 5}

No increase in complication rate due to the presence of the cantilever³

Implant-supported fixed dental prostheses with cantilevers in posterior areas are reliable long-term treatment options with a high implant survival rate²

Most common complication? Screw loosening

2. Rocuzzo, Andrea, et al. "Long-Term evaluation of implant-supported fixed dental prostheses (fdps) with cantilever extension in posterior areas. A retrospective cohort study." *Clinical Oral Implants Research*, vol. 31, no. S20, Oct. 2020, https://doi.org/10.1111/clr.26_13643.

3. Romeo E, Storelli S. Systematic review of the survival rate and the biological, technical, and aesthetic complications of fixed dental prostheses with cantilevers on implants reported in longitudinal studies with a mean of 5 years follow-up. *Clin Oral Implants Res*. 2012 Oct;23 Suppl 6:39-49. doi: 10.1111/j.1600-0501.2012.02551.x. PMID: 23062126.

4. Sadowsky, Steven J. *Evidence-Based Implant Treatment Planning and Clinical Protocols*. Wiley Blackwell, 2017.

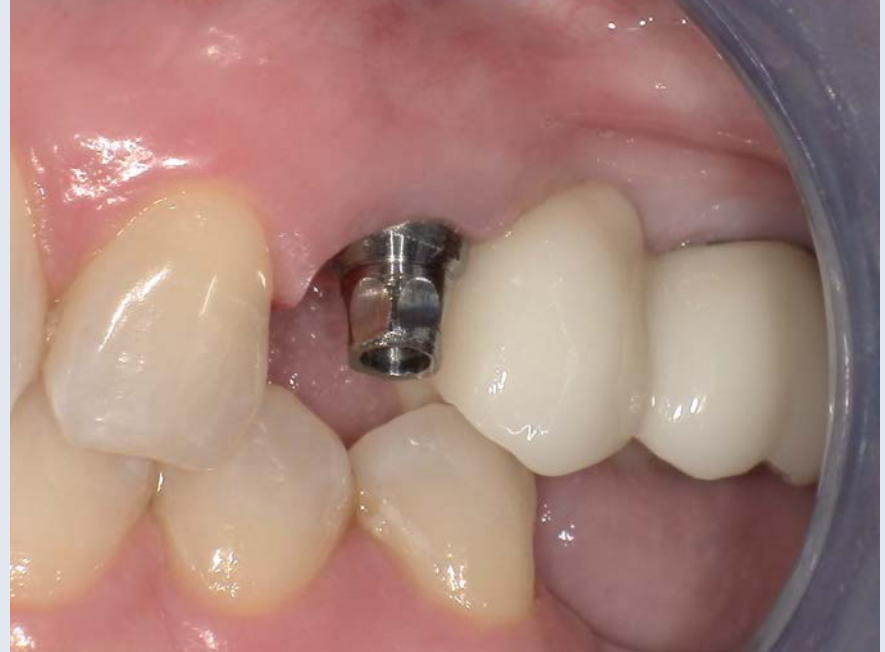5. Zurdo J, Romão C, Wennström JL. Survival and complication rates of implant-supported fixed partial dentures with cantilevers: a systematic review. *Clin Oral Implants Res*. 2009 Sep;20 Suppl 4:59-66. doi: 10.1111/j.1600-0501.2009.01773.x. PMID: 19663951.

CIMOE Attempt #5 (4/11/24)

Shade was too light, but since #12 was a stand-alone crown, it was able to be stained by Carlos mid-appointment

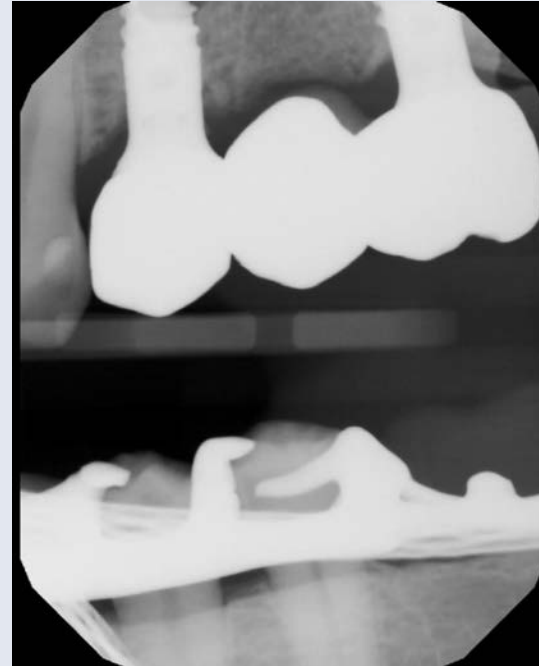
#13-#14 torqued to 35Nm and delivered while waiting for #12 staining. Patient was okay having #13-#14 lighter since they are not as visible

#12 crown delivered by the end of the appointment

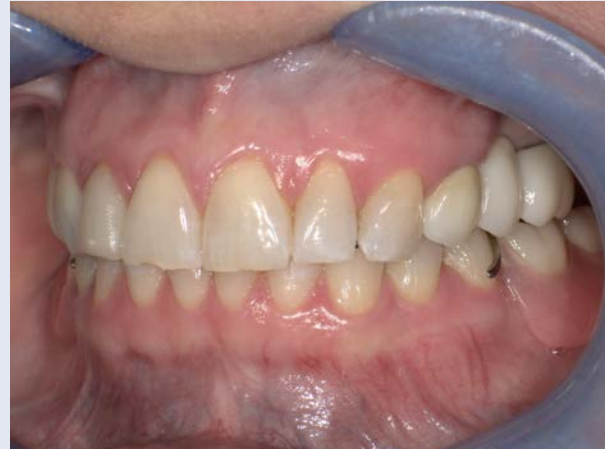
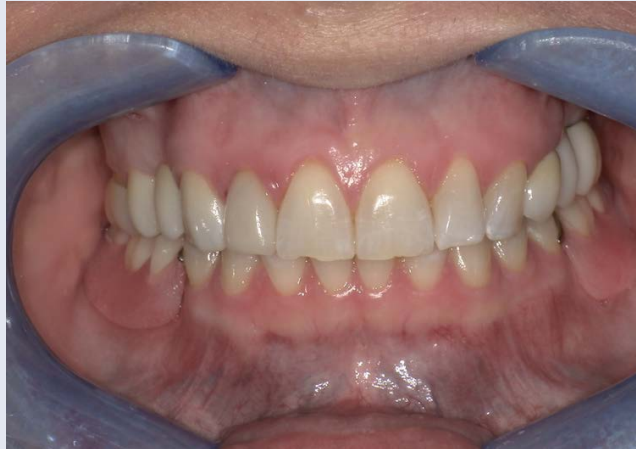
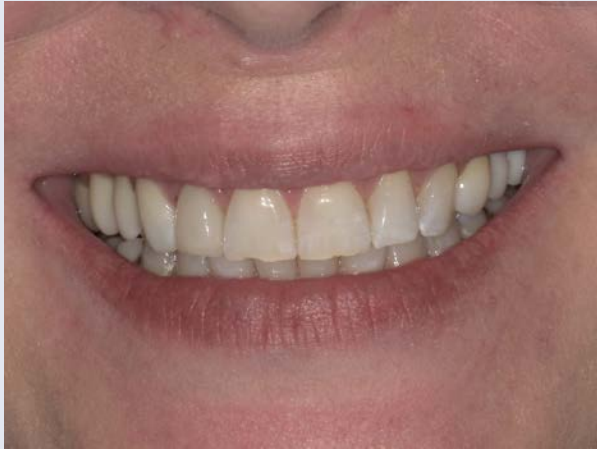CIMOE Radiograph

Restorations completely seated with no radiographic evidence of extruded cement at #12

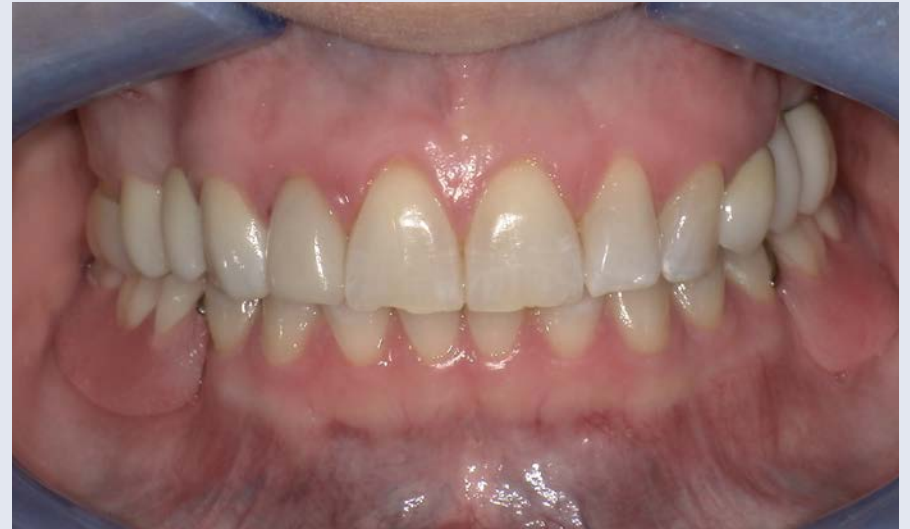
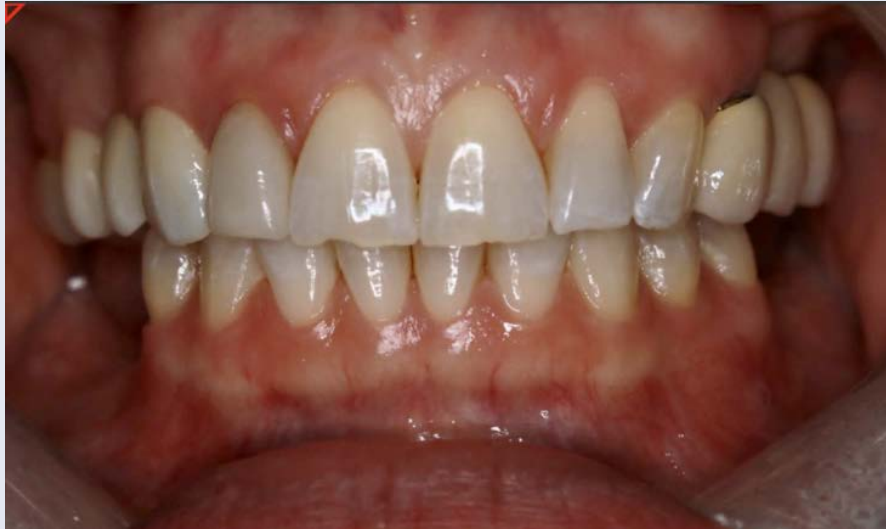
Final Photos

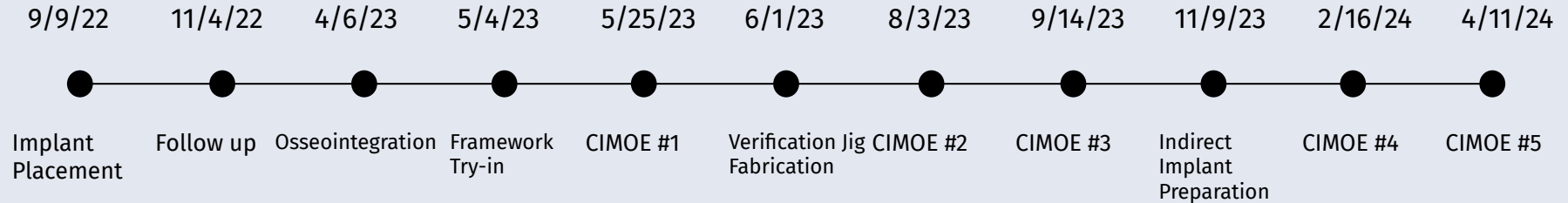

#12 shade blends in very well and patient is very happy with the outcome!

CIMOE Before vs Final



Complete Timeline



11 total appointments!

- Over 44 hours of driving
- 5 “CIMOE” appointments
- 3 different final impressions

What went wrong?

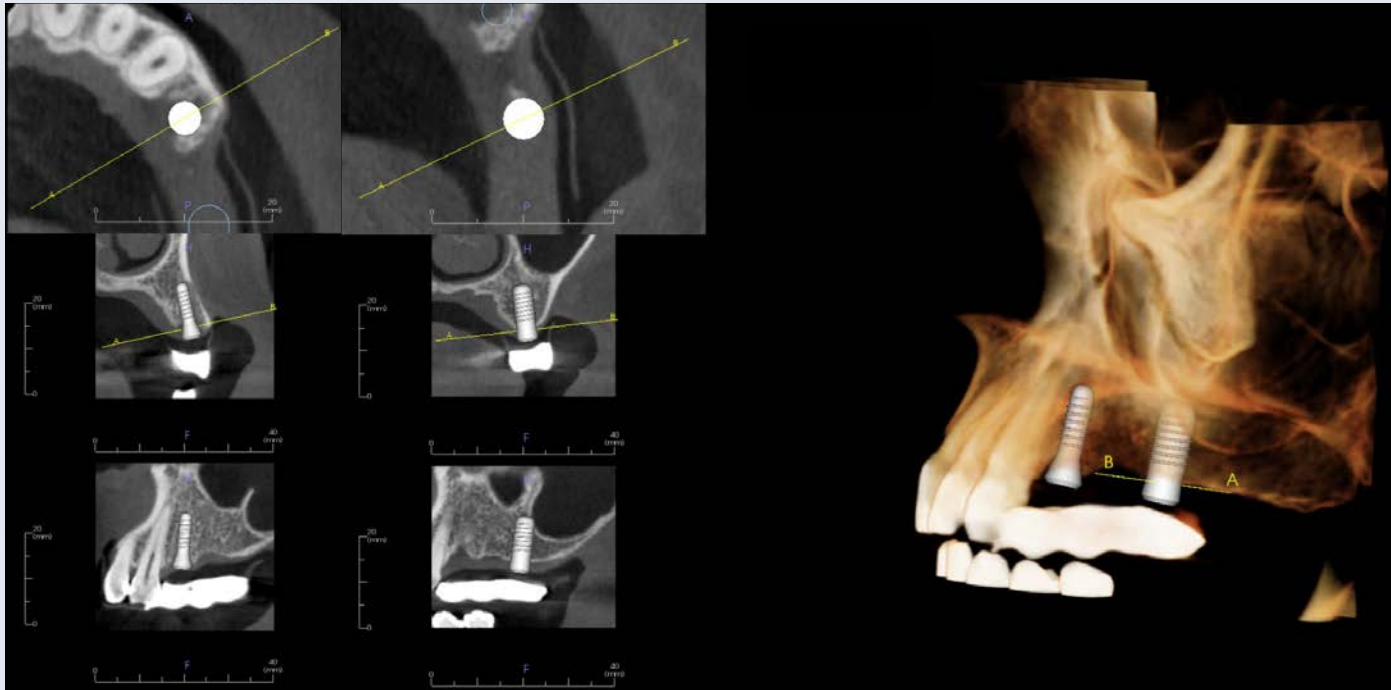
10mm implants were too long in both #12 and #14 locations

- #12: A 10mm implant angled with the screw channel exiting through the central groove would impinge on the cortical plate of the buccal bone
- #14: A “normally placed” 10mm implant would enter the sinus

So, the surgeon angled the implants more buccal to avoid these complications.

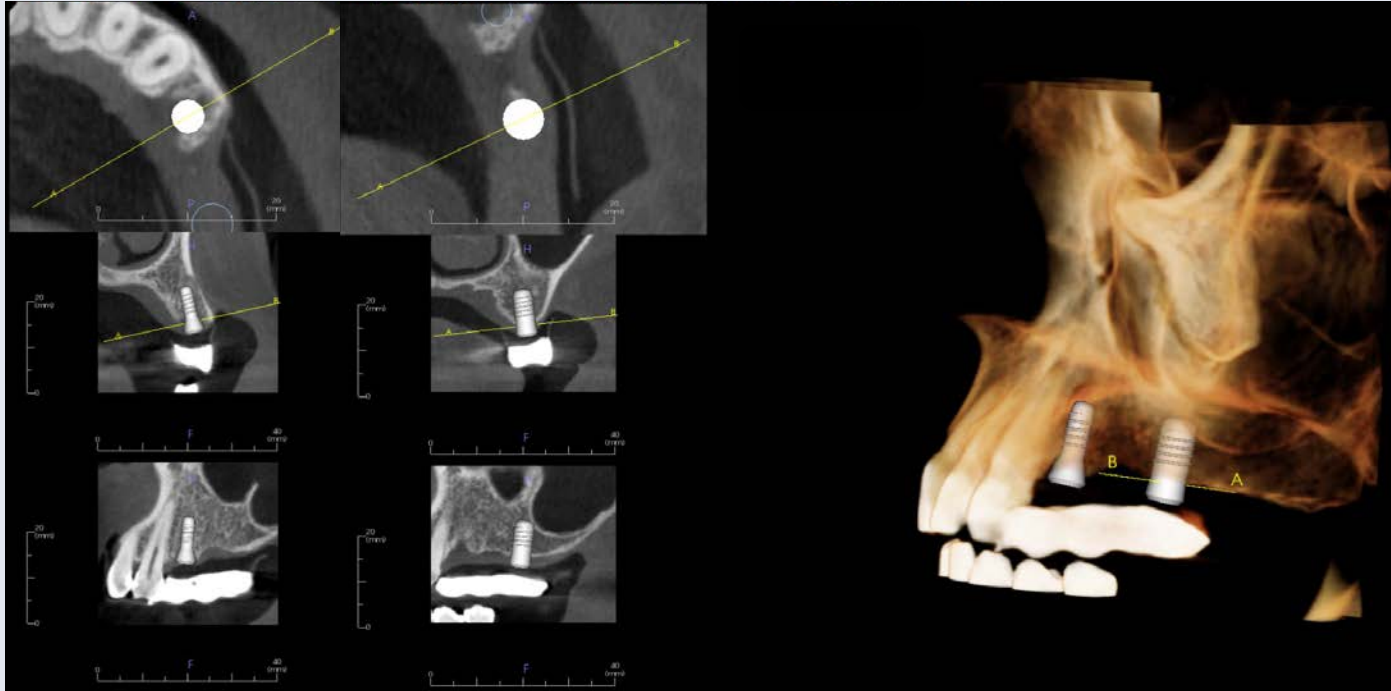
What went wrong?

Ideal situation with 10mm Implants



What should have happened?

8mm implants should have been placed instead of the 10mm implants in both locations.
#12 should have been a bone level implant rather than tissue level implant



Key Takeaways and Changes

Doing right by the patient and doing what we can to correct our mistakes

Our school no longer places tissue level implants in the premolar region

Use a Surgical guide for splinted restorations

Restoring buccally angulated implants is doable, but expect esthetic complications

References

1. Choy K, Sattler D, Daubert D, Wang IC. The effect of cement versus screw-retained implant positioning in the esthetic zone on emergence angle: A proof of principle. *Int J Periodontics Restorative Dent*. 2023 Oct 11;0(0). doi: 10.11607/prd.6903. Epub ahead of print. PMID: 37819846.
2. Roccuzzo, Andrea, et al. "Long-Term evaluation of implant-supported fixed dental prostheses (fdps) with cantilever extension in posterior areas. A retrospective cohort study." *Clinical Oral Implants Research*, vol. 31, no. S20, Oct. 2020, https://doi.org/10.1111/clr.26_13643.
3. Romeo E, Storelli S. Systematic review of the survival rate and the biological, technical, and aesthetic complications of fixed dental prostheses with cantilevers on implants reported in longitudinal studies with a mean of 5 years follow-up. *Clin Oral Implants Res*. 2012 Oct;23 Suppl 6:39-49. doi: 10.1111/j.1600-0501.2012.02551.x. PMID: 23062126.
4. Sadowsky, Steven J. *Evidence-Based Implant Treatment Planning and Clinical Protocols*. Wiley Blackwell, 2017.
5. Zurdo J, Romão C, Wennström JL. Survival and complication rates of implant-supported fixed partial dentures with cantilevers: a systematic review. *Clin Oral Implants Res*. 2009 Sep;20 Suppl 4:59-66. doi: 10.1111/j.1600-0501.2009.01773.x. PMID: 19663951.

OKU Sutro Excellence Day Project Cover Sheet

Project Title

Full name(s) and class year(s) of all project collaborators

Example: Jane Smith, DDS 2022; John Smith, DDS 2022

Project Category

Enter your abstract text here (max 300 words)