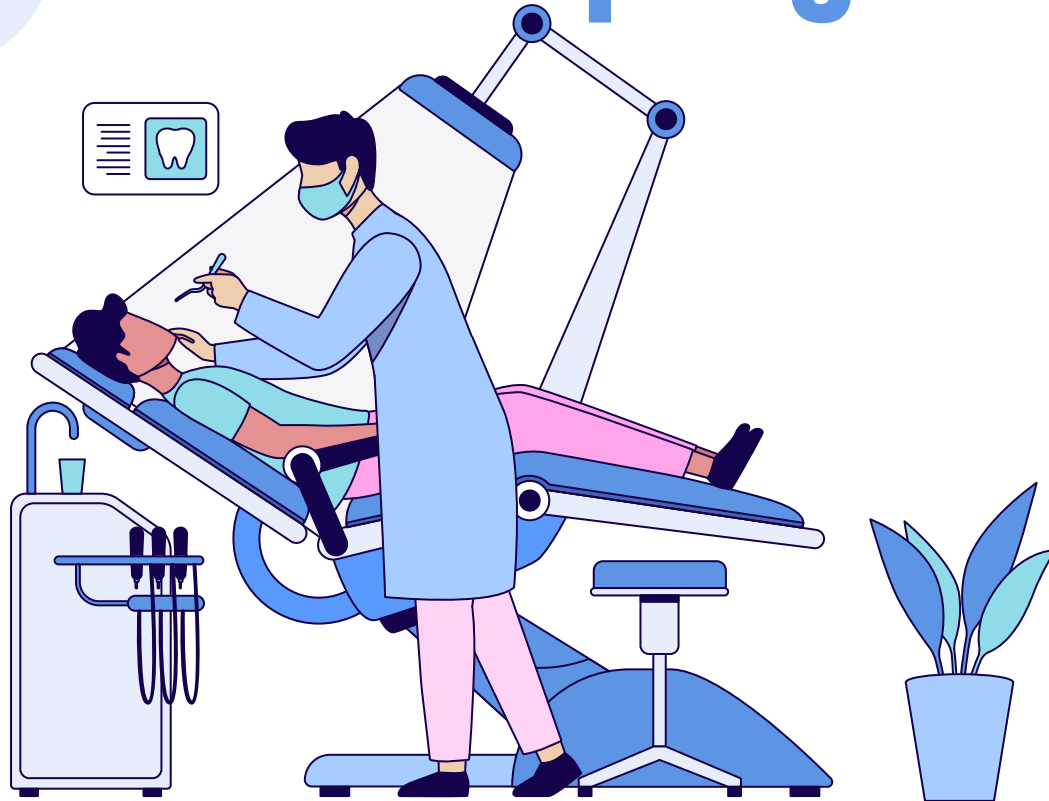

# Restoration of Oral Function in Erosive Tooth Wear Arising from Gastroesophageal Reflux Disease (GERD): A Clinical Case Study

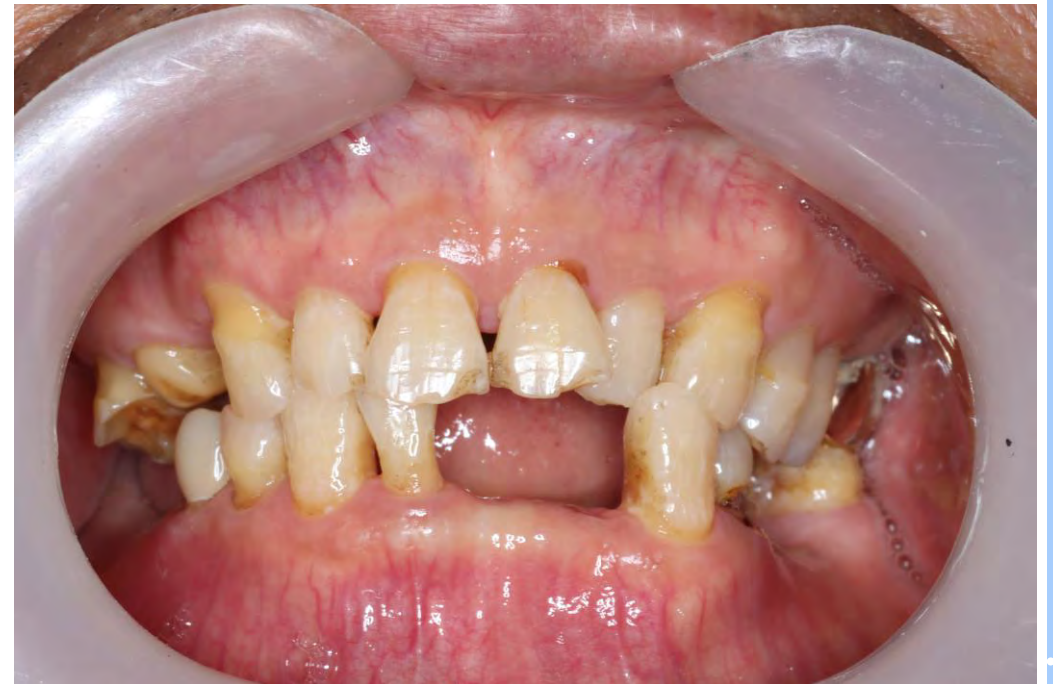

Xinyue (Cinny) Ma, Class of 2024, DDS Candidate  
University of the Pacific, Arthur A. Dugoni School of  
Dentistry, San Francisco

## Abstract

Gastroesophageal reflux disease (GERD) poses significant challenges to systemic and oral health, often resulting in **severe erosive tooth wear** and dentin hypersensitivity. This clinical case study focused on the restoration of oral function through the utilization of fixed and removable prosthetics to reconstruct the occlusal plane. The patient underwent a comprehensive treatment plan aimed at restoring lost tooth structure and restoring chewing functions. Tooth-colored composite restorations, monolithic Zirconia crowns, and partial dentures were strategically employed to rebuild the occlusal plane, alleviate dentin hypersensitivity and improve masticatory function.

This case highlights the importance of a multidisciplinary approach in managing severe tooth erosion secondary to GERD, with an emphasis on functional restoration and patient-centered care.



# Table of Contents

1

**Assessment**

2

**Findings**

3


**Treatment plan**

4

**Aftercare**


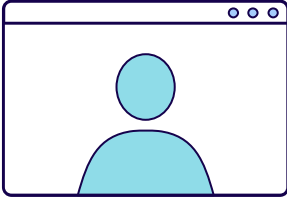
5

**Discussion**

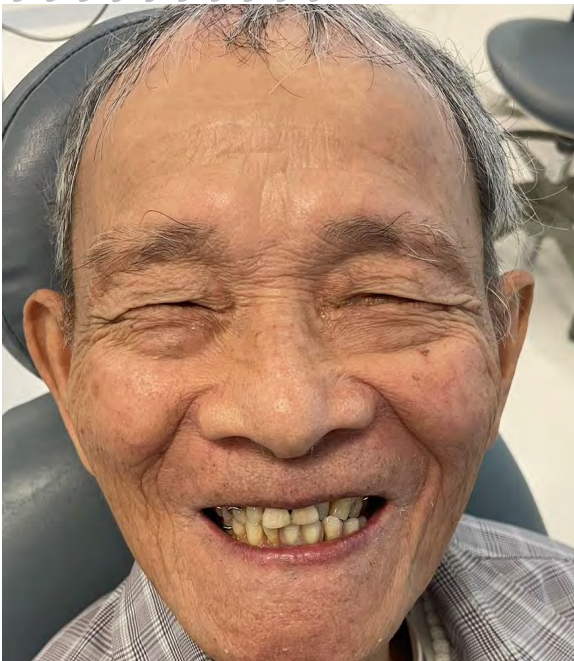

1

# Assessment

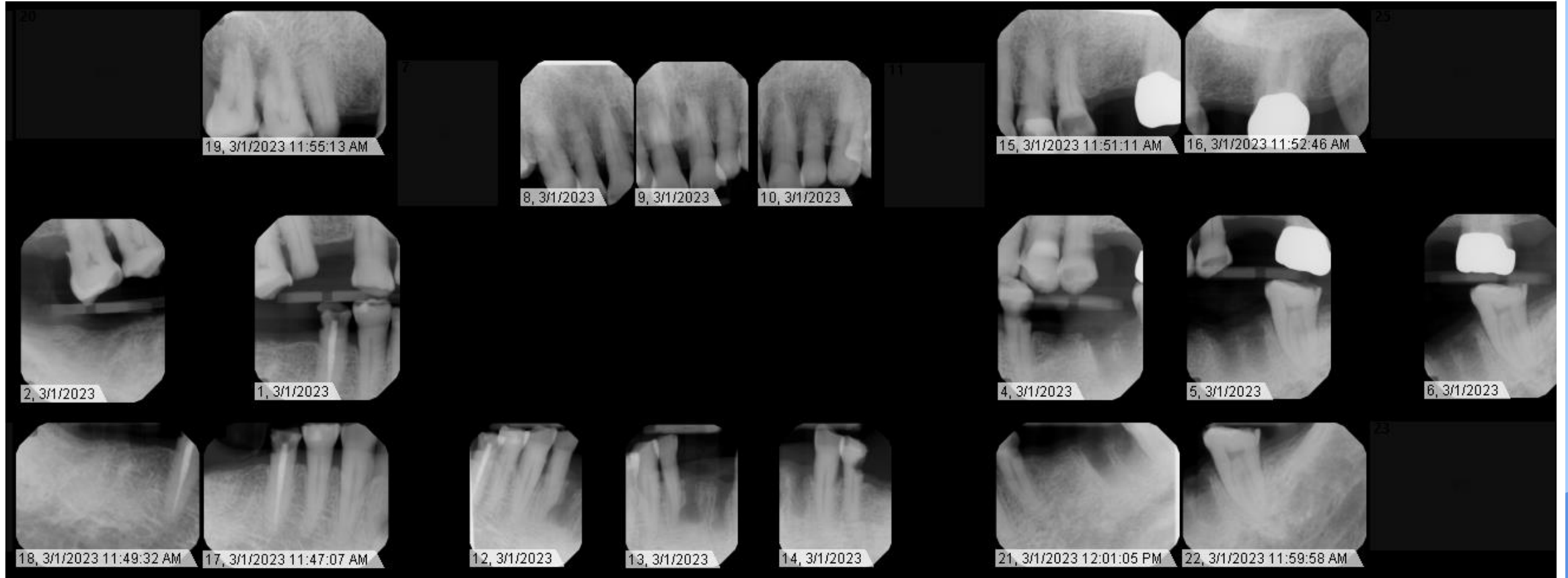


## Patient **medical history**

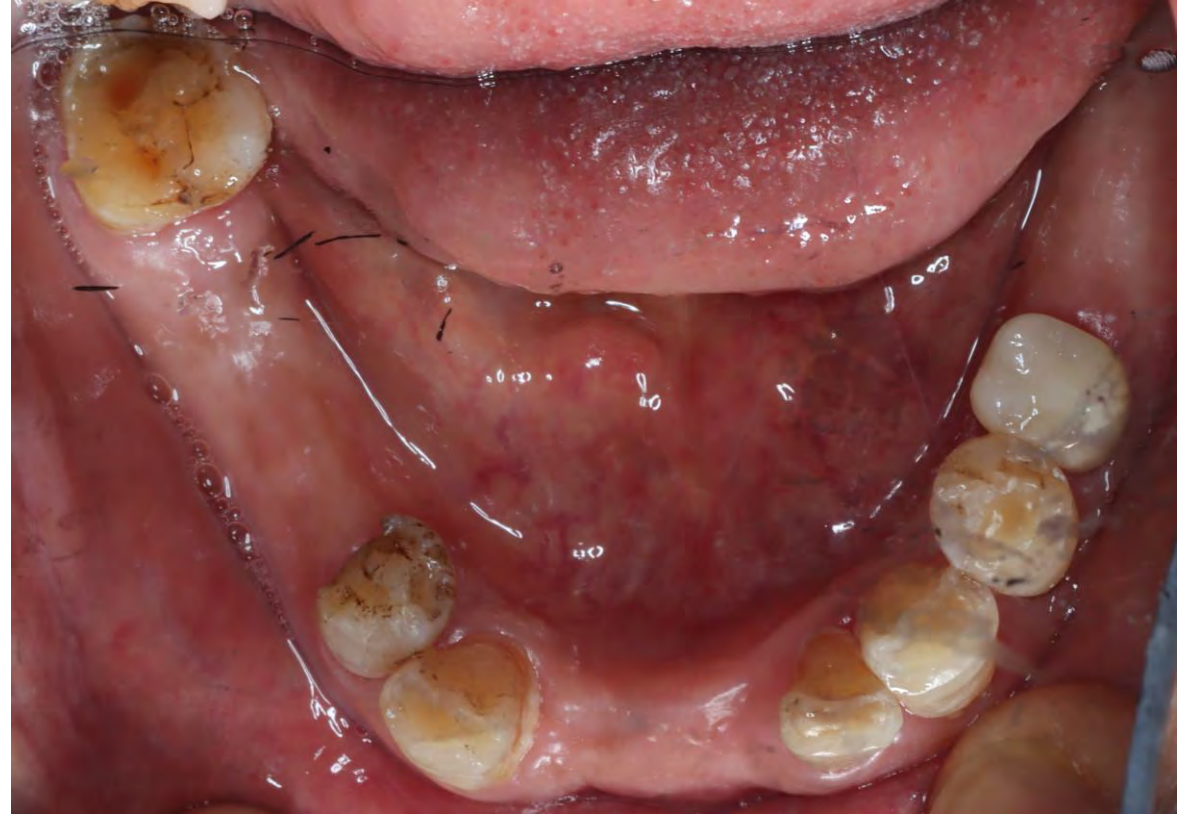
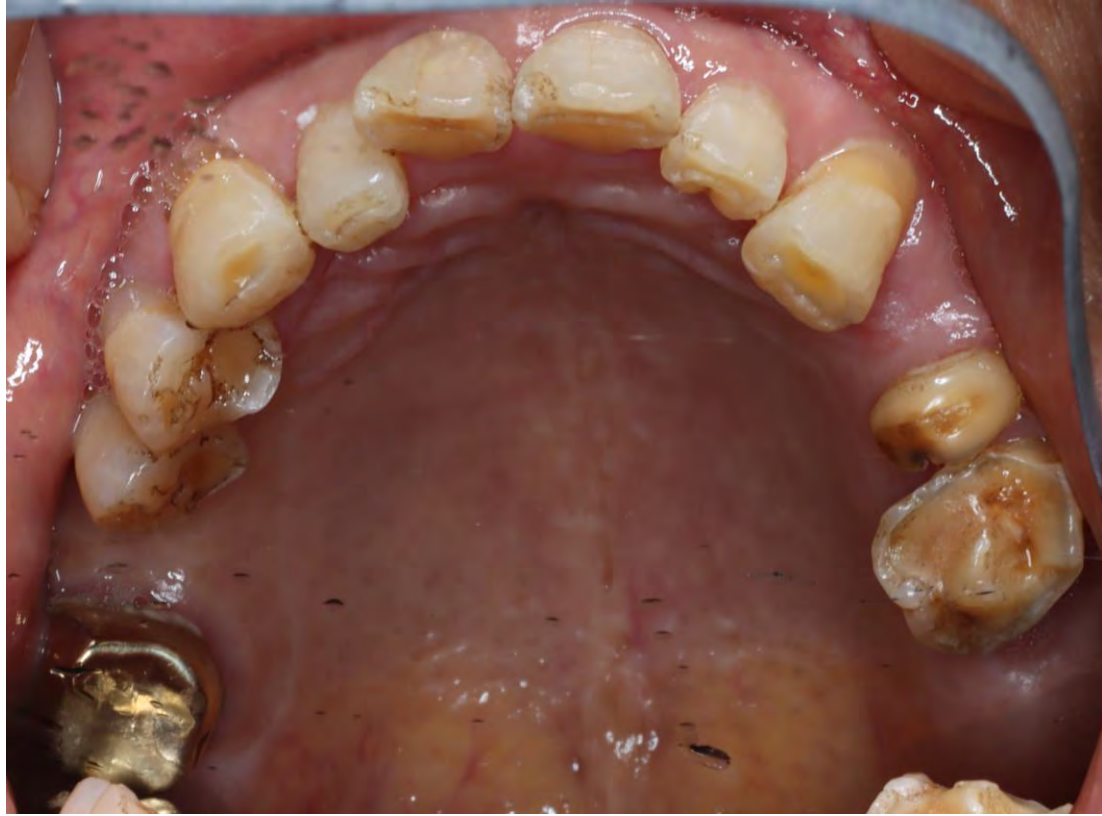
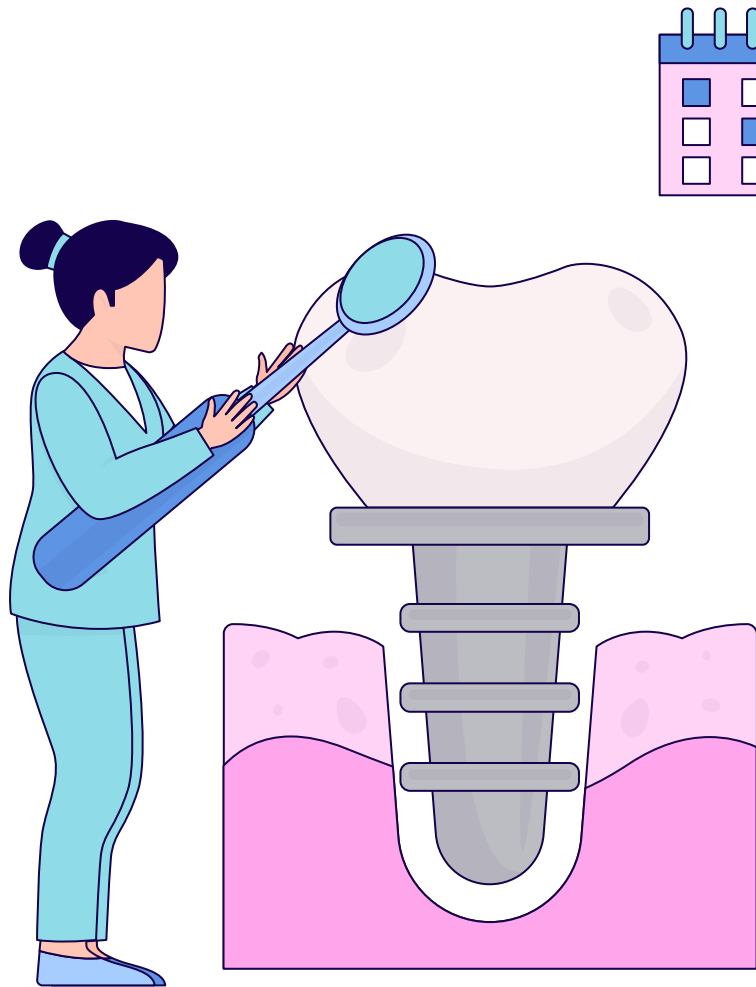<b>CC:</b>	wants to be able to chew again		
<b>Age/race/ sex:</b>	M85 Chinese	<b>Allergies</b>	NKDA
<b>MH:</b>	Arthritis on left leg and right palm, GERD	<b>Meds:</b>	Omeprazole
<b>SH:</b>	No Smoking, Not drinking alcohol, not using recreational drugs	<b>VS:</b>	112/78 mmHg, 90 bpm
	Philosophical patient w/ flexible schedule.		

# FMX









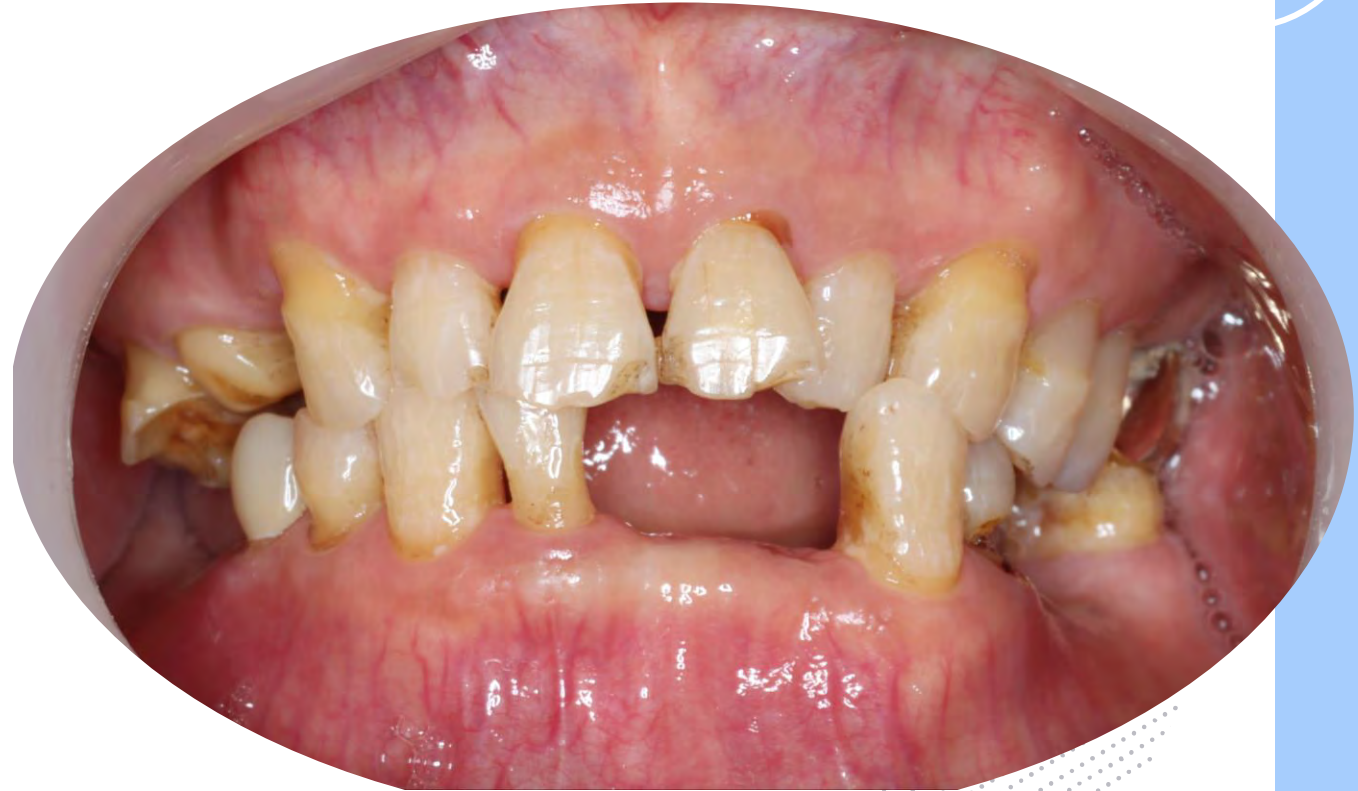2

# Findings

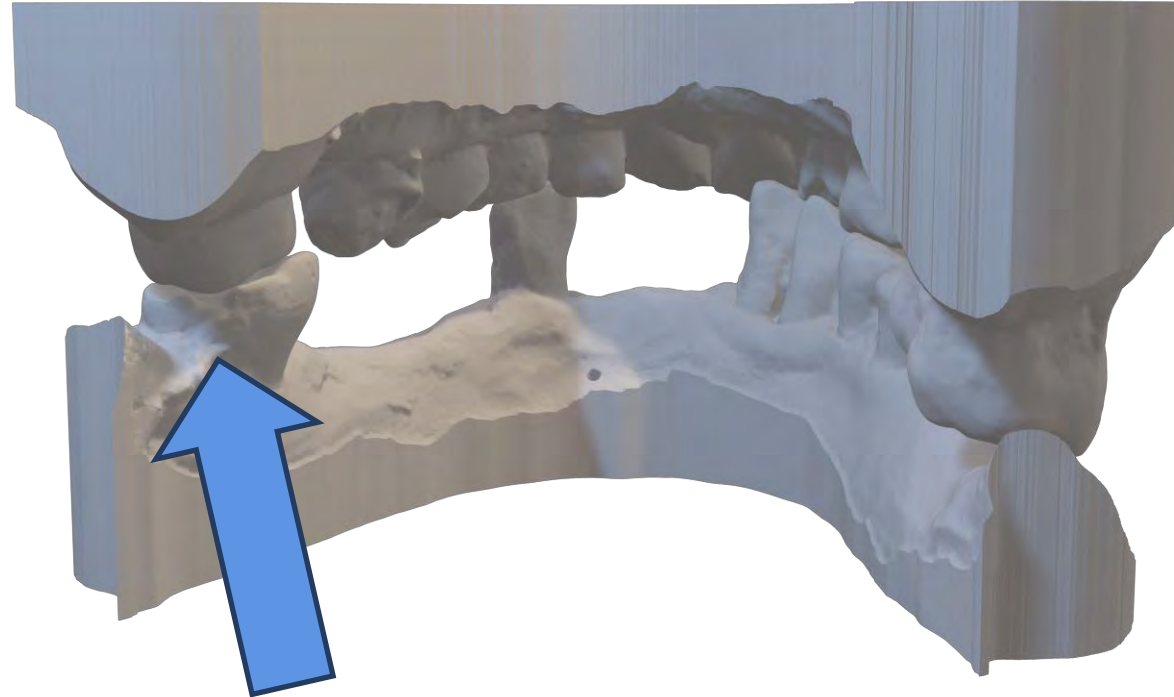


## Findings:

- Heavy Erosive tooth wear
- High caries risk
- Generalized stain
- Oral hygiene inadequate, visible plaque
- Generalized chronic moderate periodontitis
- Mild crowding on Maxillary
- Cross bite
- Maxillary and Mandibular partially edentulous

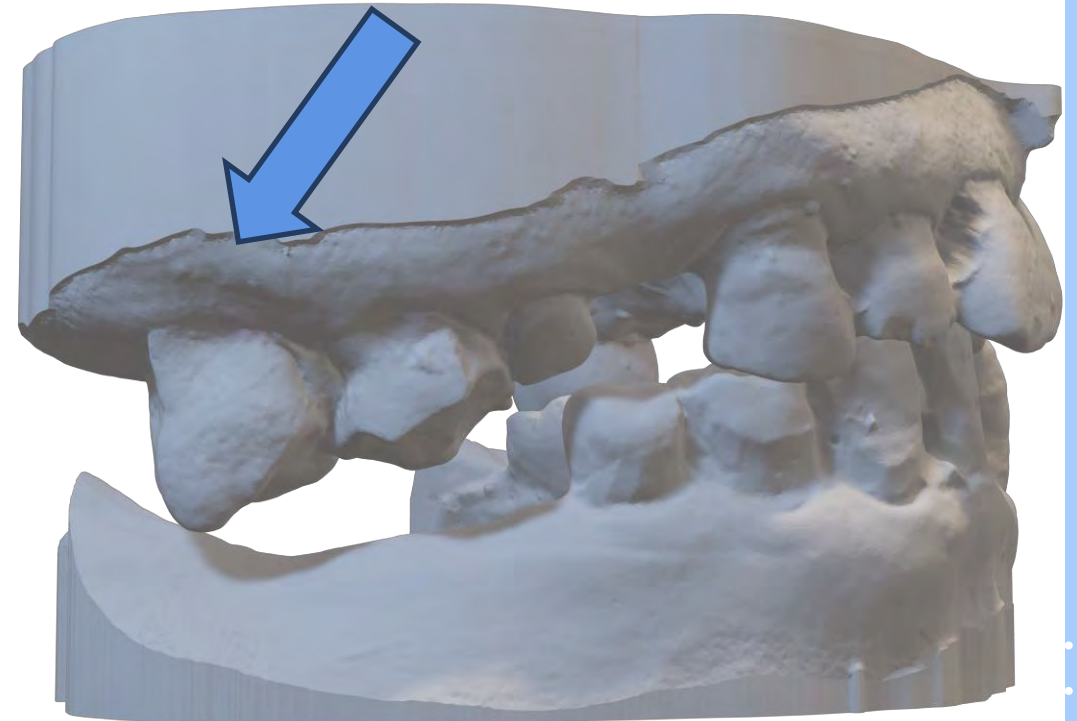


# Diagnostic models



Inverse Curve of Wilson #18

#2 Supraeruption--EXT



# Odontogram

	3 3 3	3 2 3	3 2 3		3 2 3	3 2 3	3 2 3	3 2 3	3 2 3	3 2 3	3 2 2	3 2 3	3 2 3		3 2 3	PD(F) - 04/06/2023
	4 3 3	3 3 3	3 2 3		4 3 3	3 2 3	3 3 4	4 3 3	3 2 3	3 3 3	3 3 3	4 3 3		3 3 4	PD(L) - 04/06/2023	
	1	P 2	P 3	4	5	P 6	7	P 8	P 9	10	11	12	P 13	14	P 15	16
M				M									M		M	Alerts   Problems
				3 2 3	3 2 4	3 2 4	3 2 3				3 2 3	3 2 3			3 3 2	PD(L) - 04/06/2023
				3 2 3	3 2 3	3 2 4	3 2 3				3 2 3	3 2 3			2 3 3	PD(F) - 04/06/2023



3

# Treatment plans

Ideal and Alternate treatment plan provided

# Ideal Tx plan

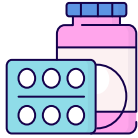Urgent phase	#21 Ext #2 Ext
Preventative Phase (Before and after Disease control phase)	CAMBRA—Prevident 5000 toothpaste, CTX spray OHI– Soft bristle toothbrush Diet Consult---Acidic food, Sugar Intake
Disease control phase	CAMRBA, OHI, Diet consult____ UL, LL quads SRP, prophy UR, LR One month ITE, OHI reinforced Stayplate Upper and Lower---Temporary #29, #18, #15, #3, #4 build-up #8 IL, #9 IL, #7 IL, #12 OL, #13 OL, #13 DB
Reconstructive phase	#29, #18, #15, #4 Survey crowns #3 Crown Implant consult –restore missing space
Maintenance Phase	Denture recall Perio recall CAMBRA products Night Guard—Bruxism

# Alternate Tx plan

Urgent phase	#2 Ext—Supraerupted #21 Ext—Gross decay
Preventative Phase (Before and after Disease control phase)	CAMBRA—Prevident 5000 toothpaste, CTX spray OHI— Soft bristle toothbrush Diet Consult---Acidic food, Sugar Intake
Disease control phase	CAMRBA, OHI, Diet consult UL, LL quads SRP, prophy UR, LR One month ITE, OHI reinforced Stayplate Upper and Lower---Temporary #29, #18, #15, #3, #4 build-up #8 IL, #9 IL, #7 IL, #12 OL, #13 OL, #13 DB
Reconstructive phase	#29, #18, #15, #4 Survey crowns #3 Crown Upper and Lower RPD
Maintenance Phase	Denture recall Perio recall CAMBRA products Night Guard—Bruxism

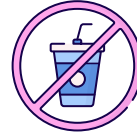

# Preventative stage



## Omeprazole

GERD under control?



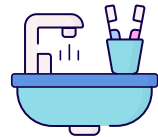## Soft drinks

Avoid drinking Soda



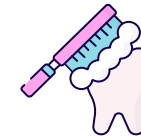## Diet

Avoid chewing on Citrus



## Lifestyle

Waiting 2–3 hours after eating before lying down



## OHI

Soft bristle toothbrush recommended, 30 min after acidic food intake

# Research support

**Zirconia** is a favored material for crowns because of its resistance to acidic environments. It is also a viable option for restoring lost tooth structure, including cases where more than **4mm of vertical dimension** has been compromised.

**Porcelain** crowns have been demonstrated to alleviate dentin hypersensitivity caused by intricate erosion patterns.

Zirconia is the material of choice due to its durability and superior strength.

AlShahrani MT, Haralur SB, Alqarni M. Restorative Rehabilitation of a Patient with Dental Erosion. *Case Rep Dent.* 2017;2017:9517486. doi: 10.1155/2017/9517486. Epub 2017 Jul 30. PMID: 28828189; PMCID: PMC5554566.

Benk I, Némethy M, Fábíán TK. Intrinsic erosio okozta foganyagveszteség helyreállítása porcelánborító koronákkal. Esetismertetés [Restoration of profound tooth damage caused by intrinsic erosion, with porcelain crowns. A case report]. *Fogorv Sz.* 2011 Sep;104(3):81-5. Hungarian. PMID: 22039713.

[Case Rep Dent](#). 2017; 2017: 9517486. Published online 2017 Jul 30. doi: [10.1155/2017/9517486](#)

PMCID: PMC5554566 | PMID: [28828189](#)

## Restorative Rehabilitation of a Patient with Dental Erosion

[Mohammed Thamer AlShahrani](#), <sup>1</sup> [Satheesh B. Haralur](#), <sup>2,\*</sup> and [Mohammed Alqarni](#) <sup>3</sup>

[▶ Author information](#) [▶ Article notes](#) [▶ Copyright and License information](#) [PMC Disclaimer](#)

### Abstract

[Go to:](#)

Dental erosion is the chemical dissolution of the tooth structure. Factors like eating disorders and gastrointestinal diseases are recognized as intrinsic factors for dental erosion. Advanced stages of dental erosion extensively damage the tooth morpholog

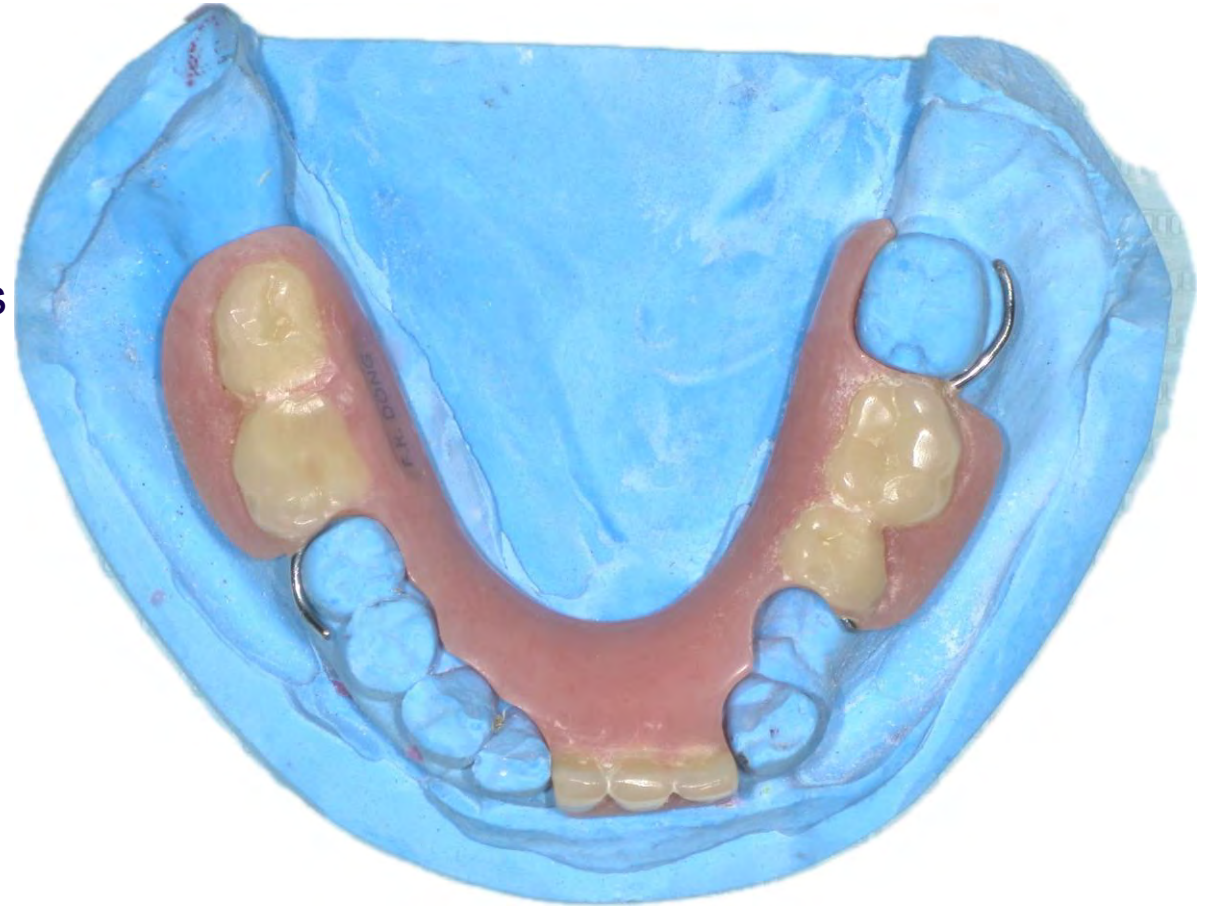The screenshot shows a PubMed article page. At the top, the PubMed logo is visible with 'Advanced User Guide' and a search icon. Below the logo, there is a breadcrumb trail: 'Case Reports > Fogorv Sz. 2011 Sep;104(3):81-5.'. The main title of the article is '[Restoration of profound tooth damage caused by intrinsic erosion, with porcelain crowns. A case report]'. Below the title, it indicates '[Article in Hungarian]' and lists the authors: 'Irén Benk <sup>1</sup>, Miklós Némethy, Tibor Károly Fábíán'. There are links for 'Affiliations + expand' and 'PMID: 22039713'. At the bottom of the article preview, there are three buttons: 'Cite', a menu icon (three dots), and a settings icon (gear). The abstract text is visible below these buttons.

### Abstract

In the presented case extensive tooth damage has been caused by an eating disorder (bulimia nervosa coupled with frequent vomiting). Although the patient's premised disorder has been treated successfully, palatal and occlusal surfaces of the upper teeth were profoundly damaged

# Stayplate-temporary

- Stabilize posterior occlusion
- Esthetic needs
- No chewing function support
- For patient to adapt removable prosthetics

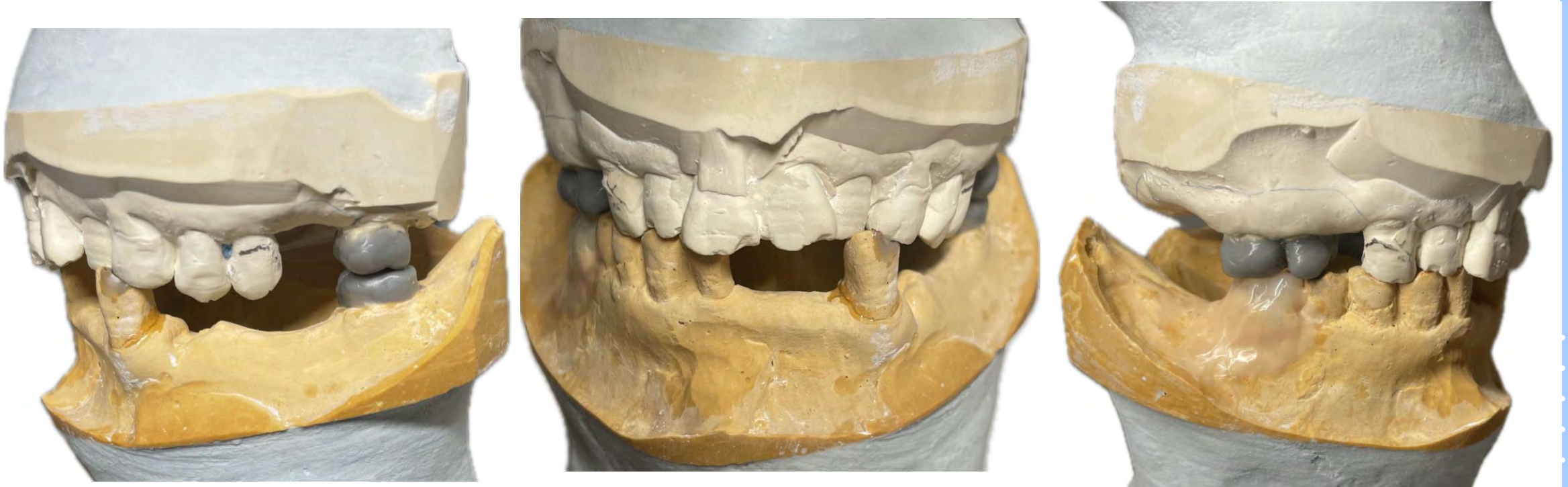

# Comprehensive tx plan

Provider	Diagnosis	Procedure	Procedure Description	Site	Surf.	Phase	Seq.
D24289	Generalized Moderate	D4341	Scaling/rt planing 4 or more	UL			1
D24289	Generalized Moderate	D4341	Scaling/rt planing 4 or more	LL			1
D24290	Plaque induced gingi	D1110	Prophy - adult / tooth structures and implants				1
D24289	Generalized Moderate	D0180P	ITE Comprehensive Periodontal Eval - \$0				2
D24289	Generalized Moderate	D4910	Periodontal maintenance				3
D24289	Primary active moder	D2392	Resin-based comp-2 surf, post.	21	DO		4
D24290	Primary active moder	D2392	Resin-based comp-2 surf, post.	29	DO		4
D24290	Primary active moder	D2391	Resin-based comp-1 surf, post.	13	B		4
D24289	Primary active moder	D2752	Crown - PFM noble metal	29	MODBL		5
D24289	Primary active moder	L2752-1	Crown-PFM-noble	29	MODBL		5
D24289	Sensitive dentin	D2752	Crown - PFM noble metal	2	MODBL		5
D24289	Sensitive dentin	L2752-1	Crown-PFM-noble	2	MODBL		5
D24289	Sensitive dentin	D2752	Crown - PFM noble metal	3	MODBL		5
D24289	Sensitive dentin	L2752-1	Crown-PFM-noble	3	MODBL		5
D24289	Sensitive dentin	D2752	Crown - PFM noble metal	18	MODBL		5
D24289	Sensitive dentin	L2752-1	Crown-PFM-noble	18	MODBL		5
D24289	Insufficient clinica	M41899B	Extraction, erupted tth/ exp rt	4			6
D24290	Defective maxillary	D5213	Max partial - cast metal frame	UA			7
D24290	Defective maxillary	L5213-1	RPD-max, cast	UA			7
D24289	Defective mandibular	D5214	Mand partial -cast metal frame	LA			7
D24289	Defective mandibular	L5214-1	RPD-mand, cast	LA			7
			Estimated Total				

## Diagnostic Models with wax-up

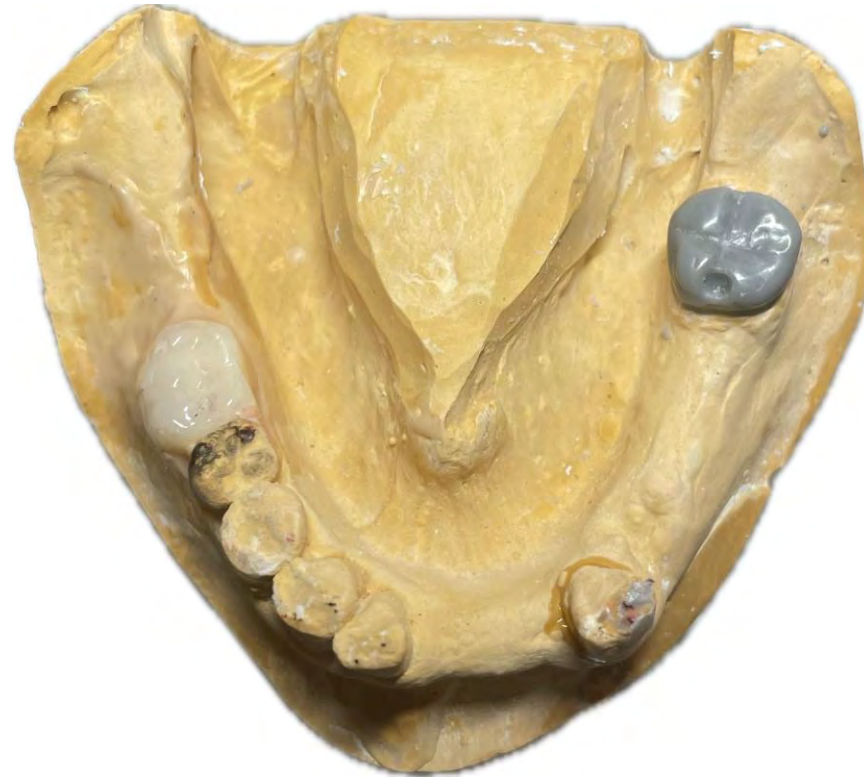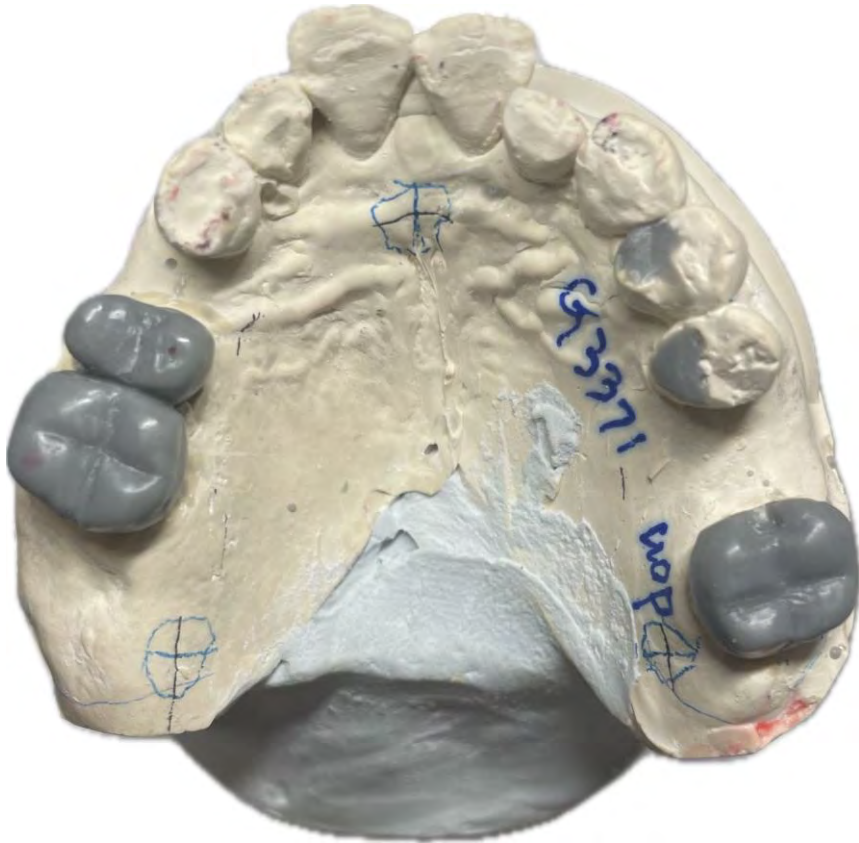- Correct inverse curve of Wilson #18
- Assess occlusal reduction including rest preps areas
- Restore proper occlusal plane





# Diagnostic Models with wax-up

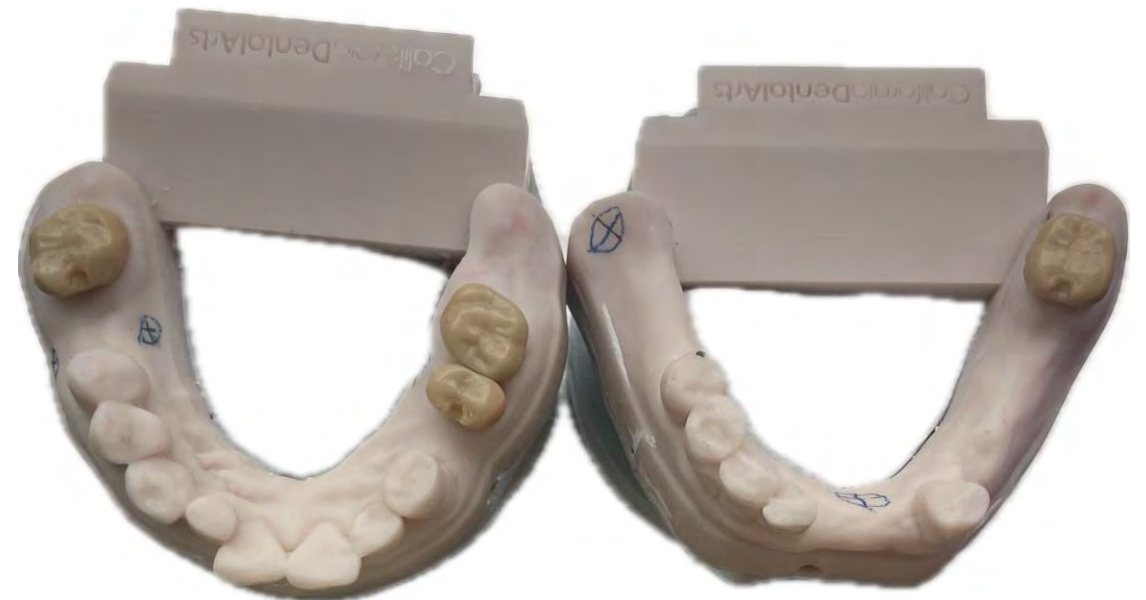Survey crowns: #29, #18, #15, #4





# Diagnostic Models with wax-up

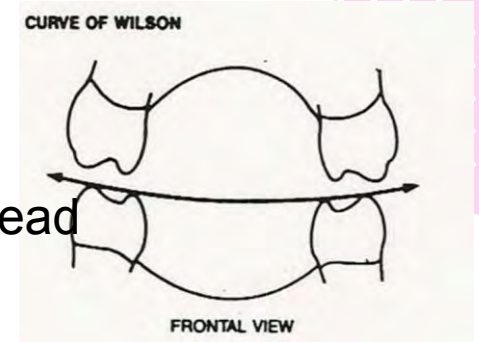
- Correct the inverse curve of Wilson #18
- Assess occlusal reduction including rest preps areas
- Restore proper occlusal plane
- Fabricating temps to alleviate dentin hypersensitivity
- Design Undercuts and rest preps better fit with RPD



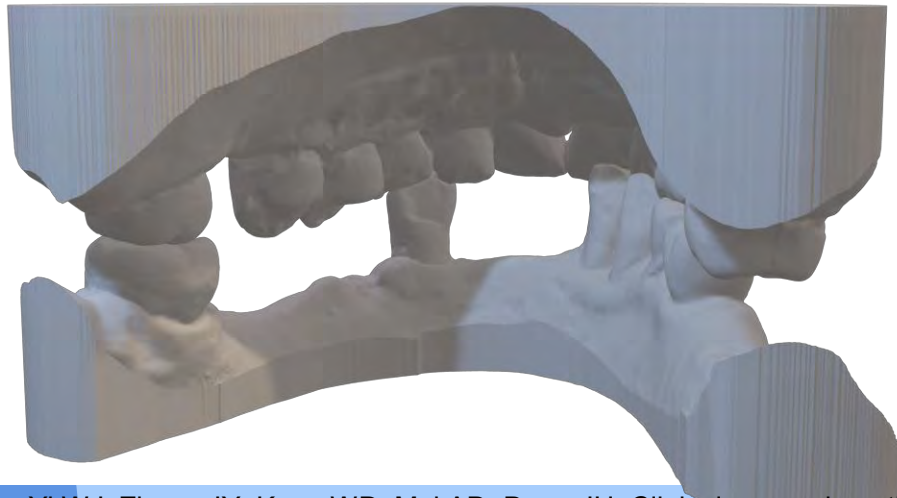
# Negative Curve of Wilson

Functions of the Curve of Wilson:


1. Protect the posterior occlusion during the lateral excursion
2. Prevent fracture of restorative due to parafunction,
3. Negative curve of Wilson will impact the temporomandibular joint (TMJ) and lead to the development of TMD



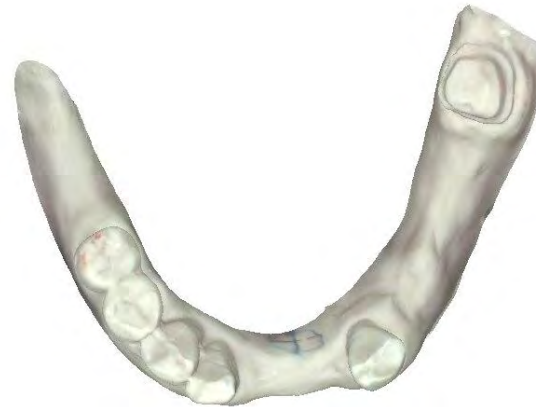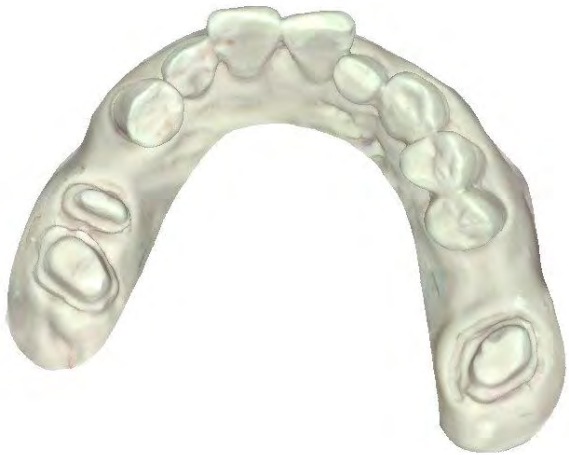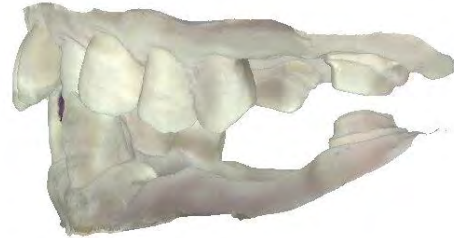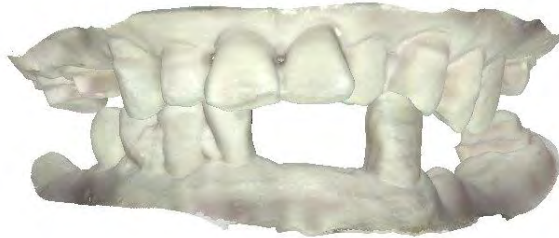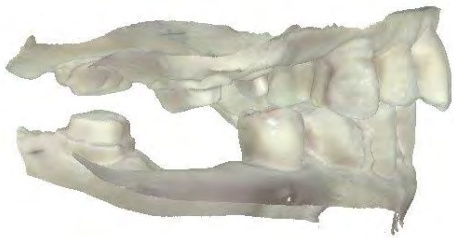Corrected Curve



Reverse Curve of Wilson #18



# Digital Cast with Crown Preps



# Digital Cast with Crown Preps



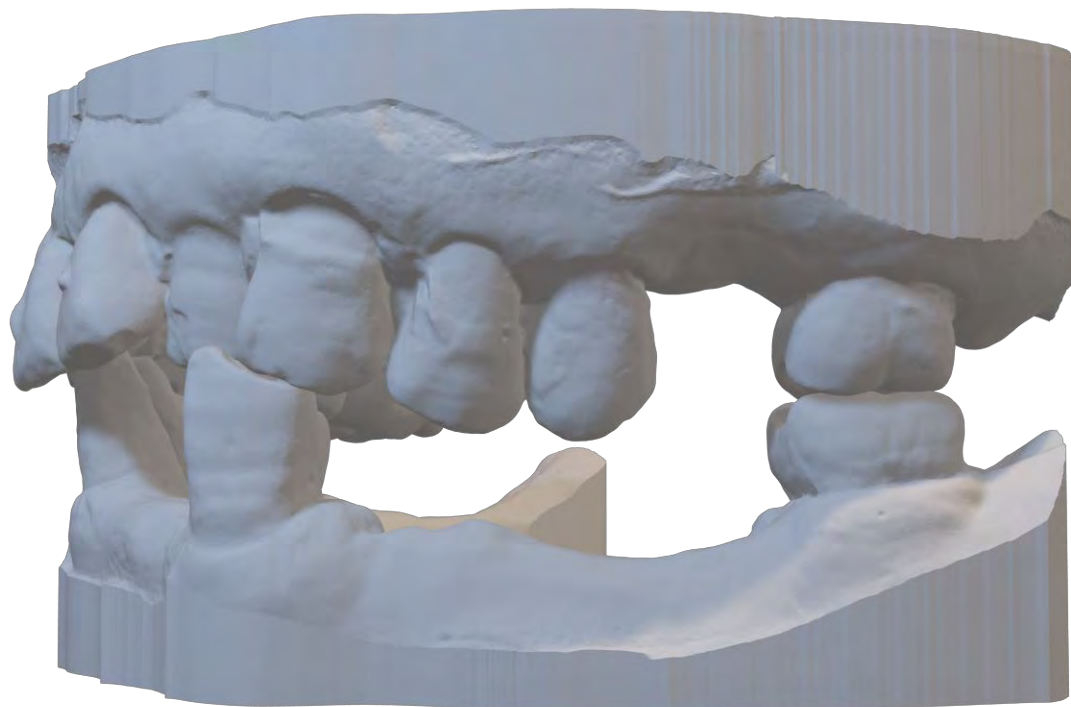
STL file, need 3D viewer

**Pros:** **Supragingival margins** is proved to be related to better gingival health, including less bleeding and recession.

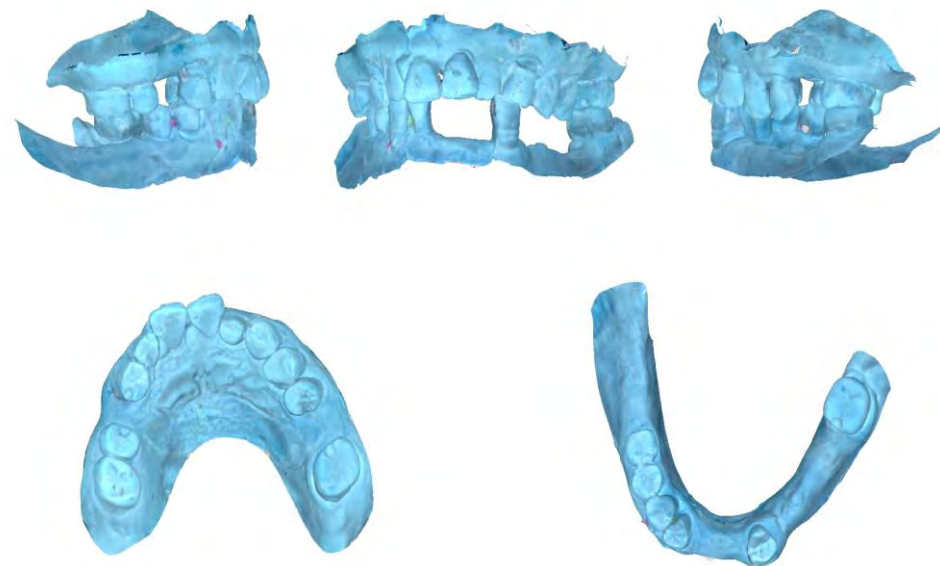
**Cons:** Prep retention is undermines. Grooves may be added to prep for mechanical retention. Bonding before cementing final crowns can also increase retention.

Orkin DA, Reddy J, Bradshaw D. The relationship of the position of crown margins to gingival health. J Prosthet Dent. 1987 Apr;57(4):421-4. doi: 10.1016/0022-3913(87)90006-0. PMID: 3553564.

## Mastercast with Crown delivered

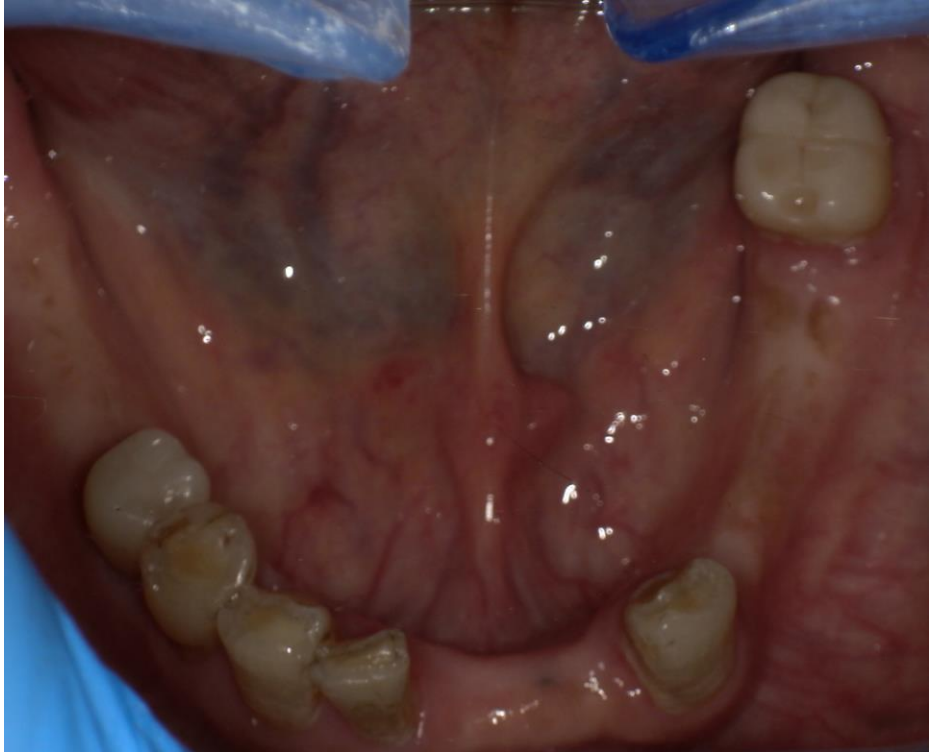
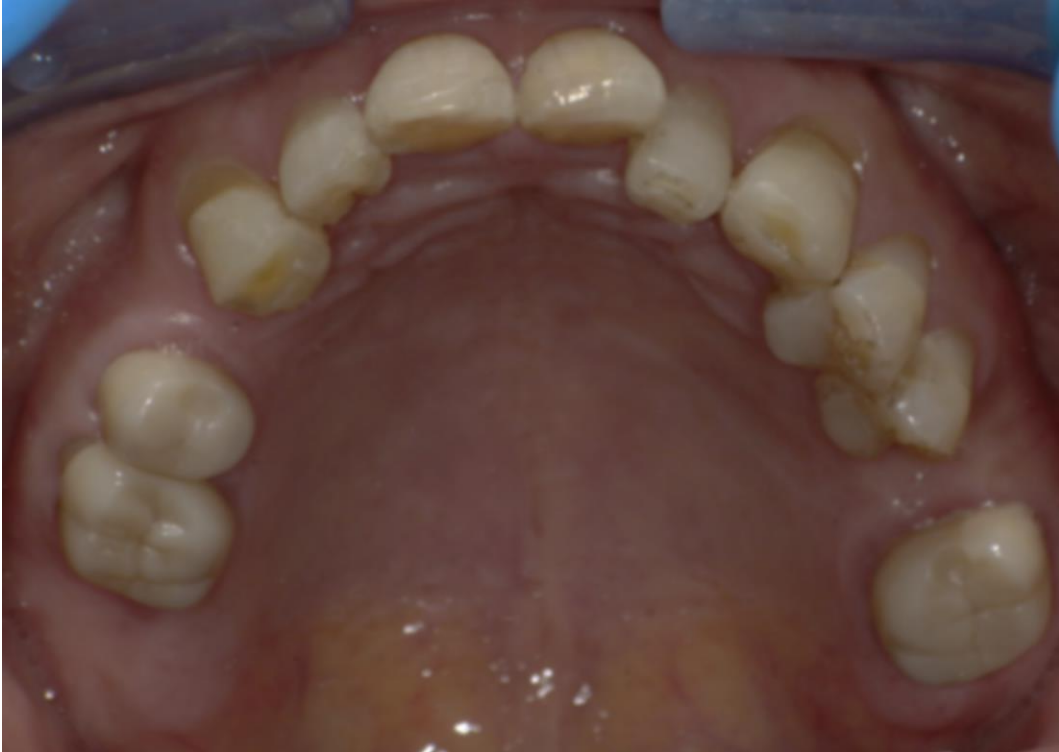
STL file, need 3D viewer



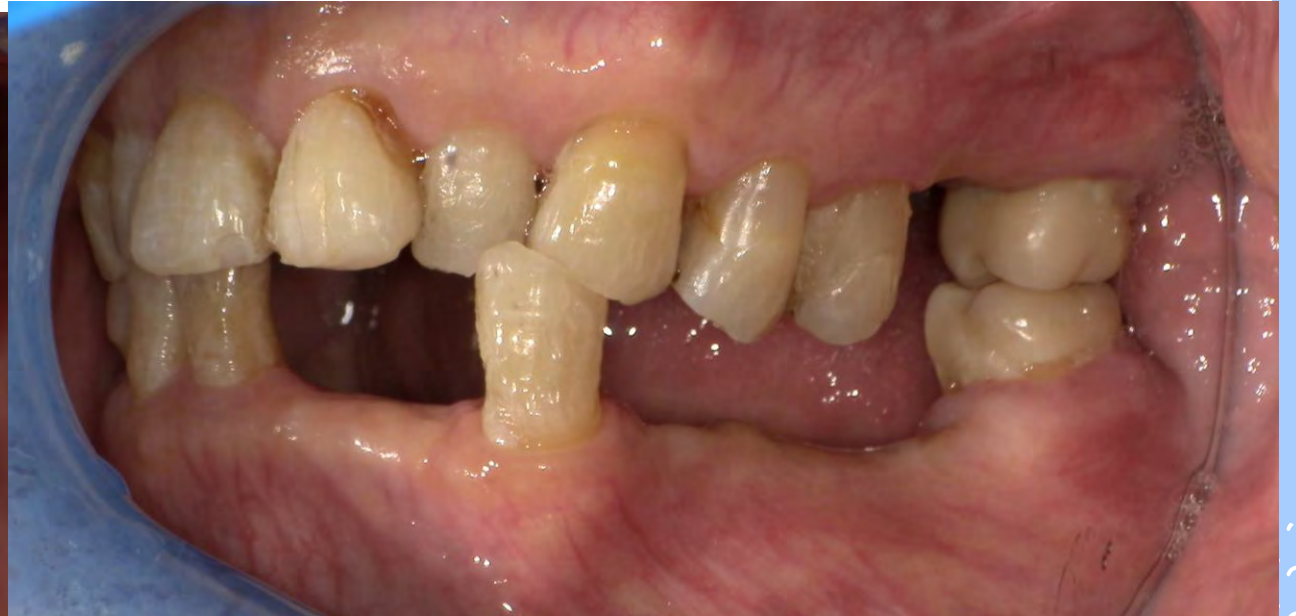
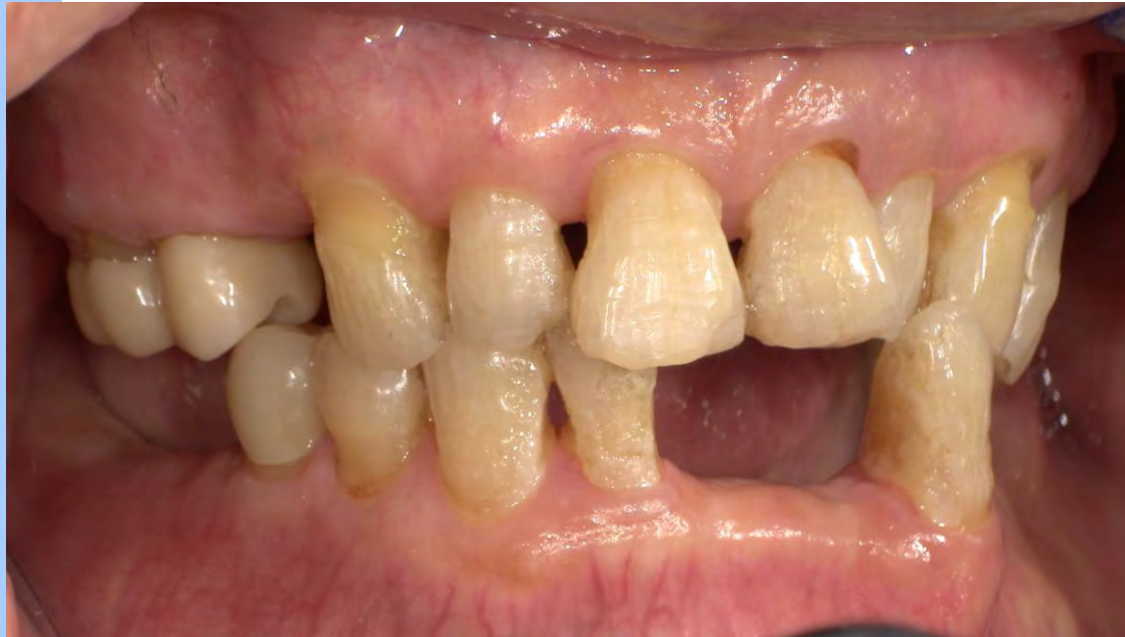
# Post-opt photos (with crowns delivered)





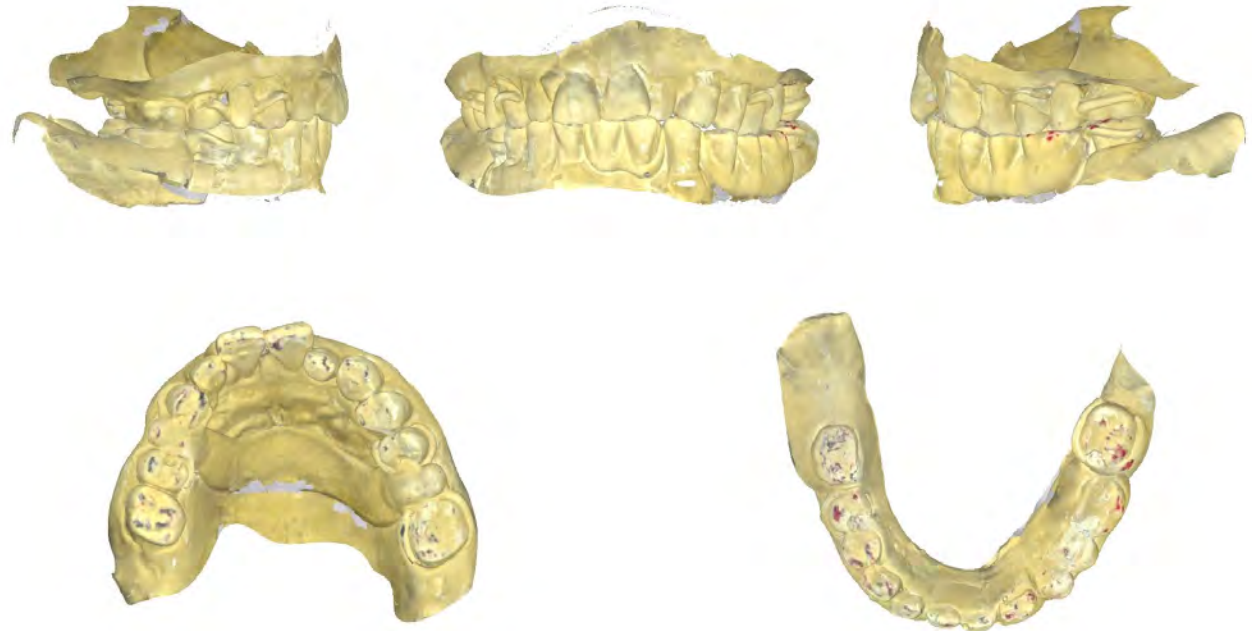## Post-opt photos (with crowns delivered)



## Final Result Casts with RPD

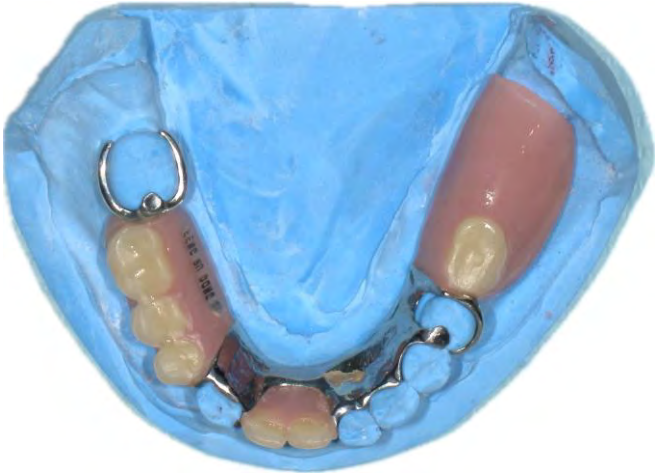
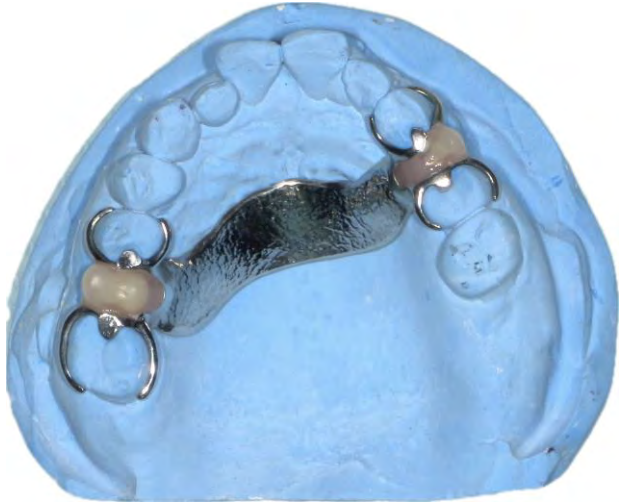
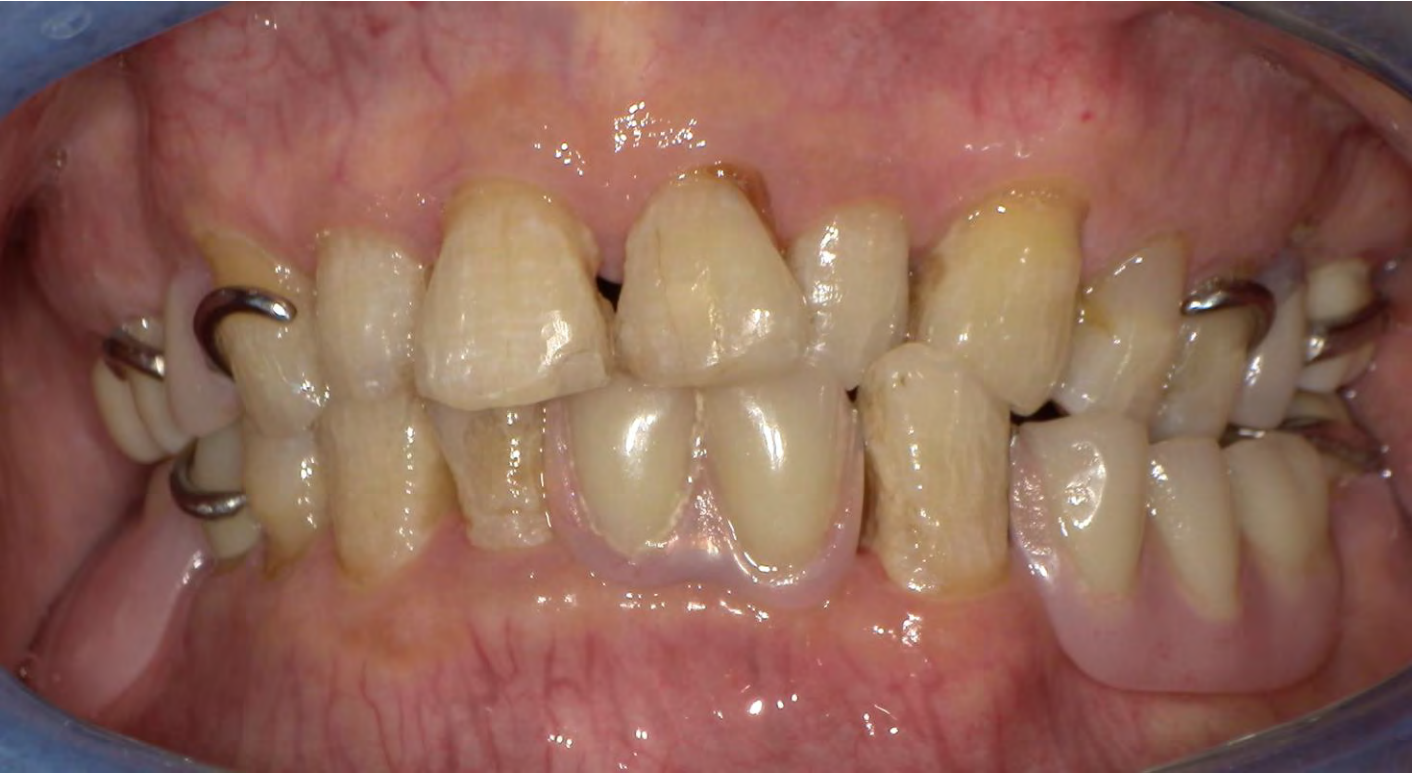STL file, need 3D viewer



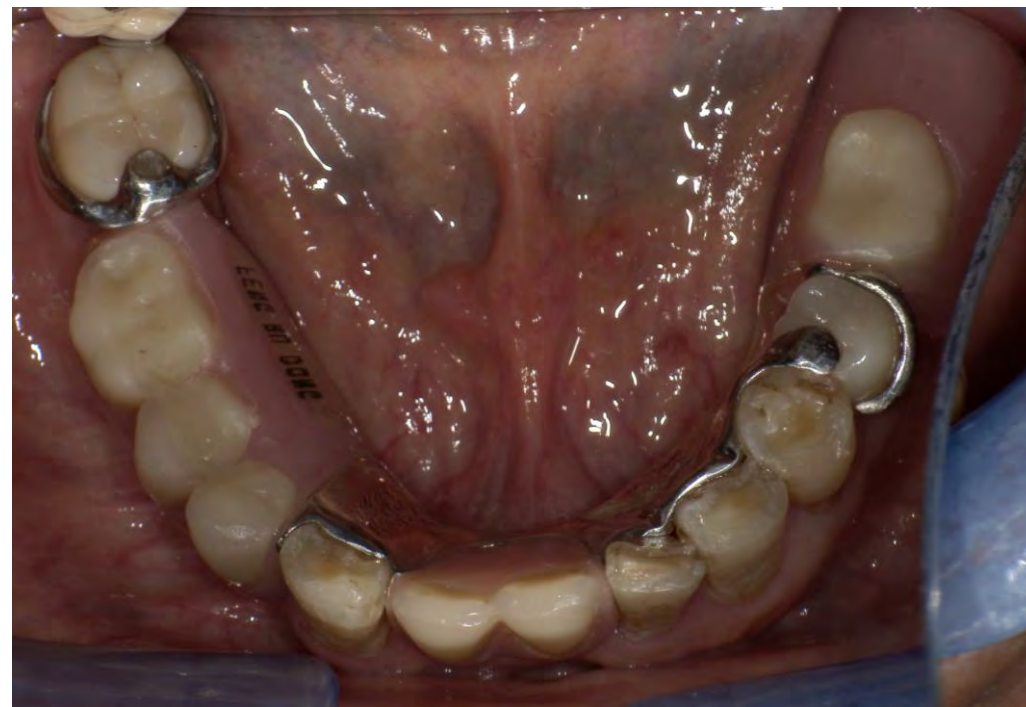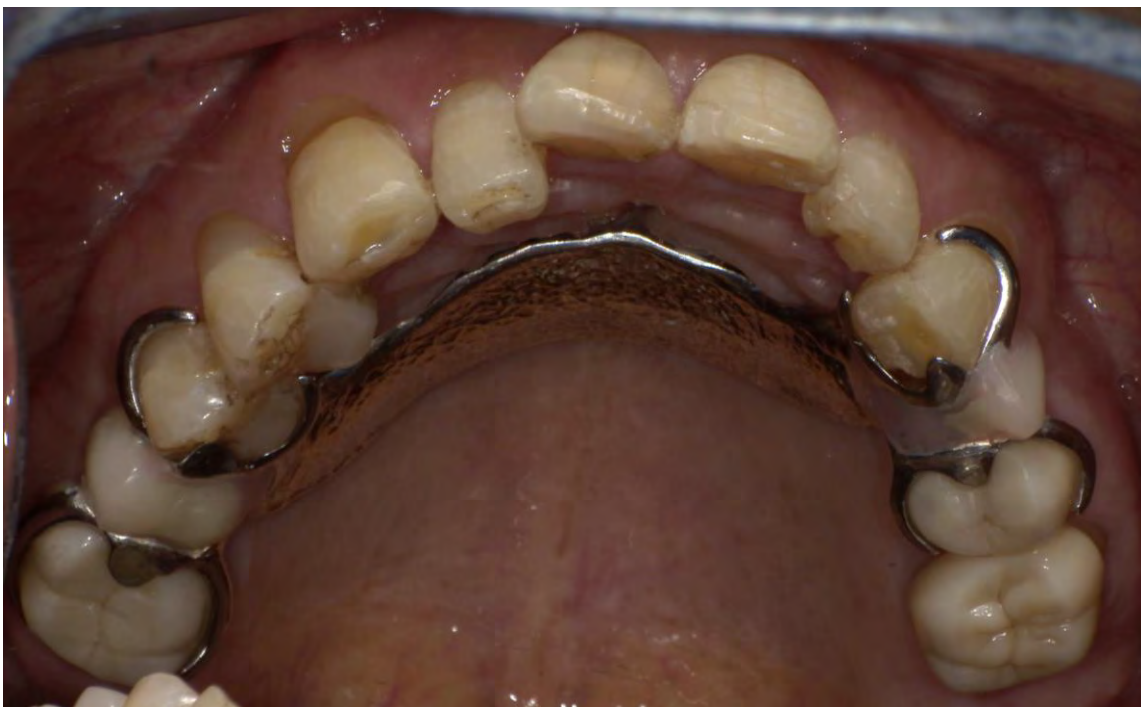93% patients tolerate maxillary palatal bar best instead of plating design, for the most satisfying speaking, chewing, swallowing functions. Health of tissue

# Post-opt photos (with RPD)

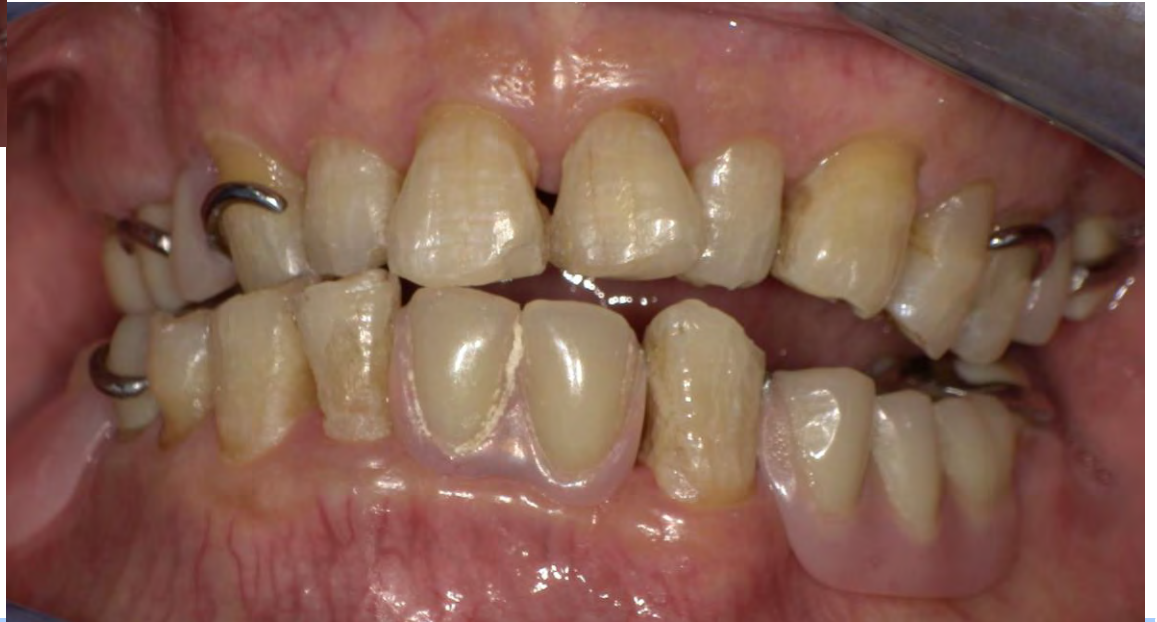
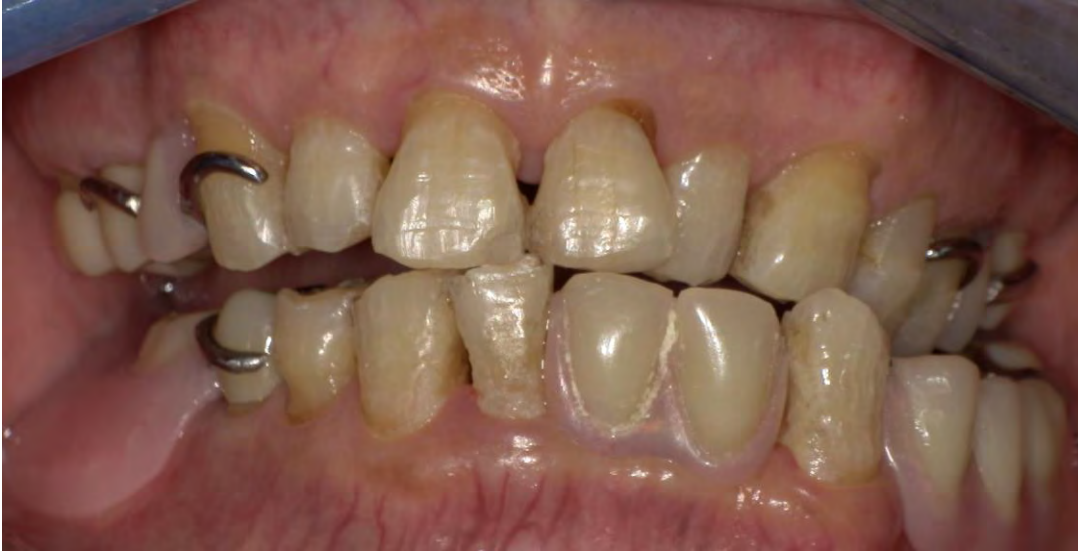


## Post-opt photos (with RPD)

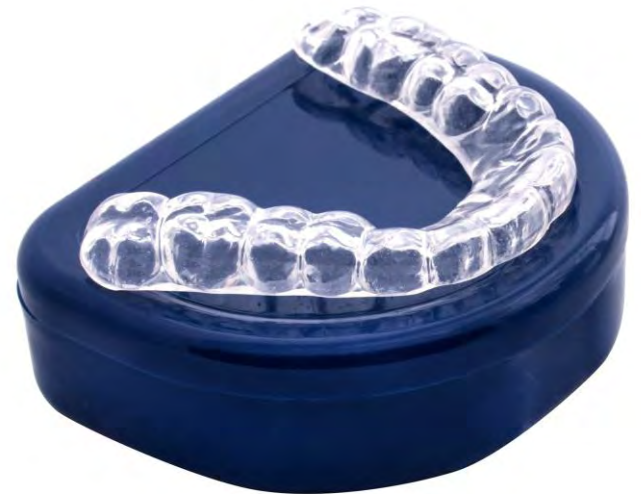

## Excursions and protrusions (with RPD)



# Night guard

1. Using a night guard is essential in preventing further damage to teeth from grinding during sleep, which jeopardized existing anterior guidance.
2. In cases where acid reflux is unmanaged and a patient experiences noticeable acidity in their mouth at night, applying fluoride to the occlusal splint during nighttime wear can be beneficial.

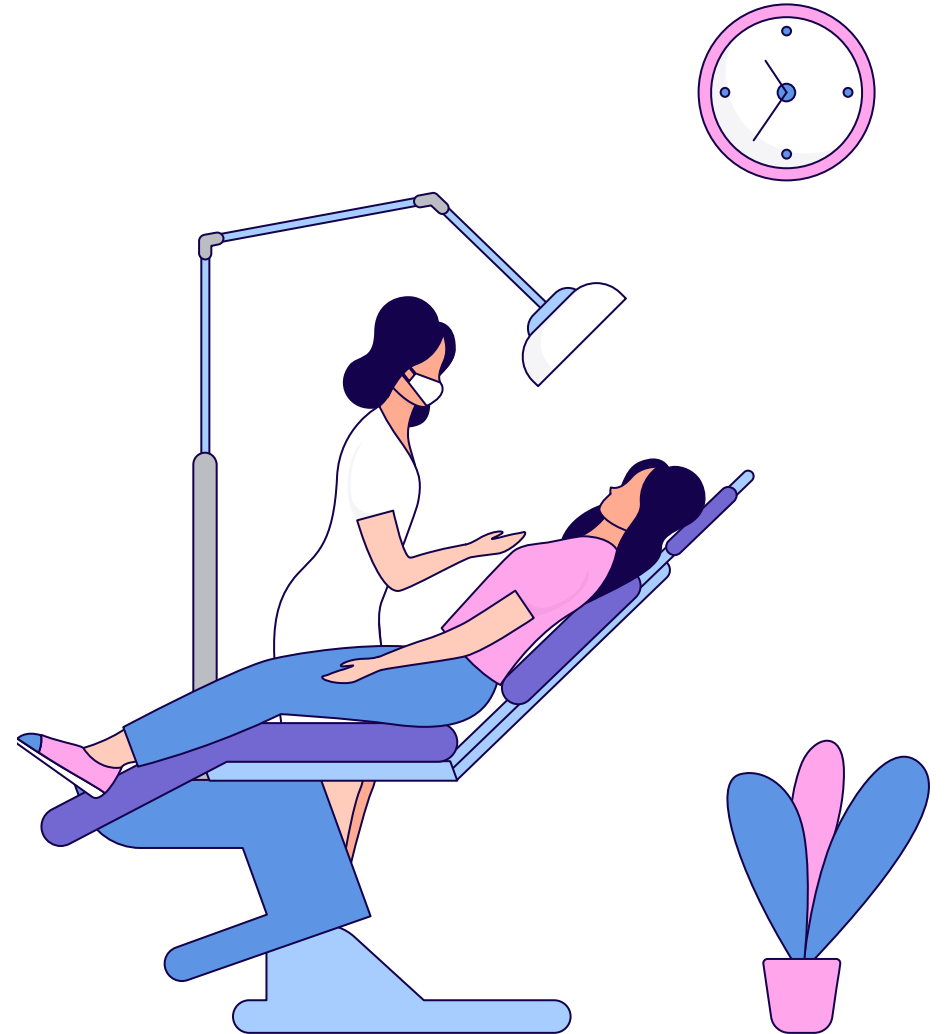



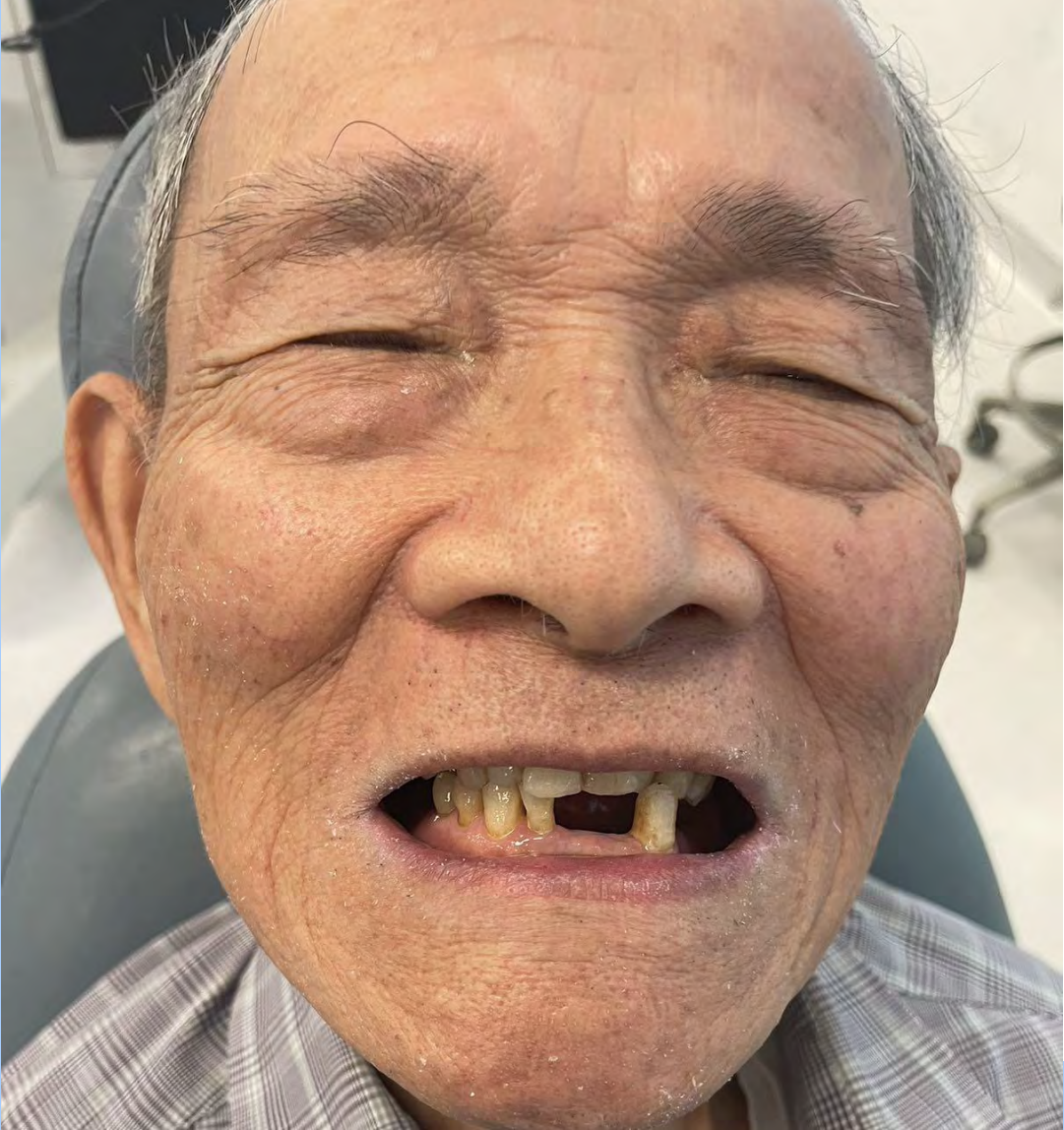# Are we done yet?

Aftercare

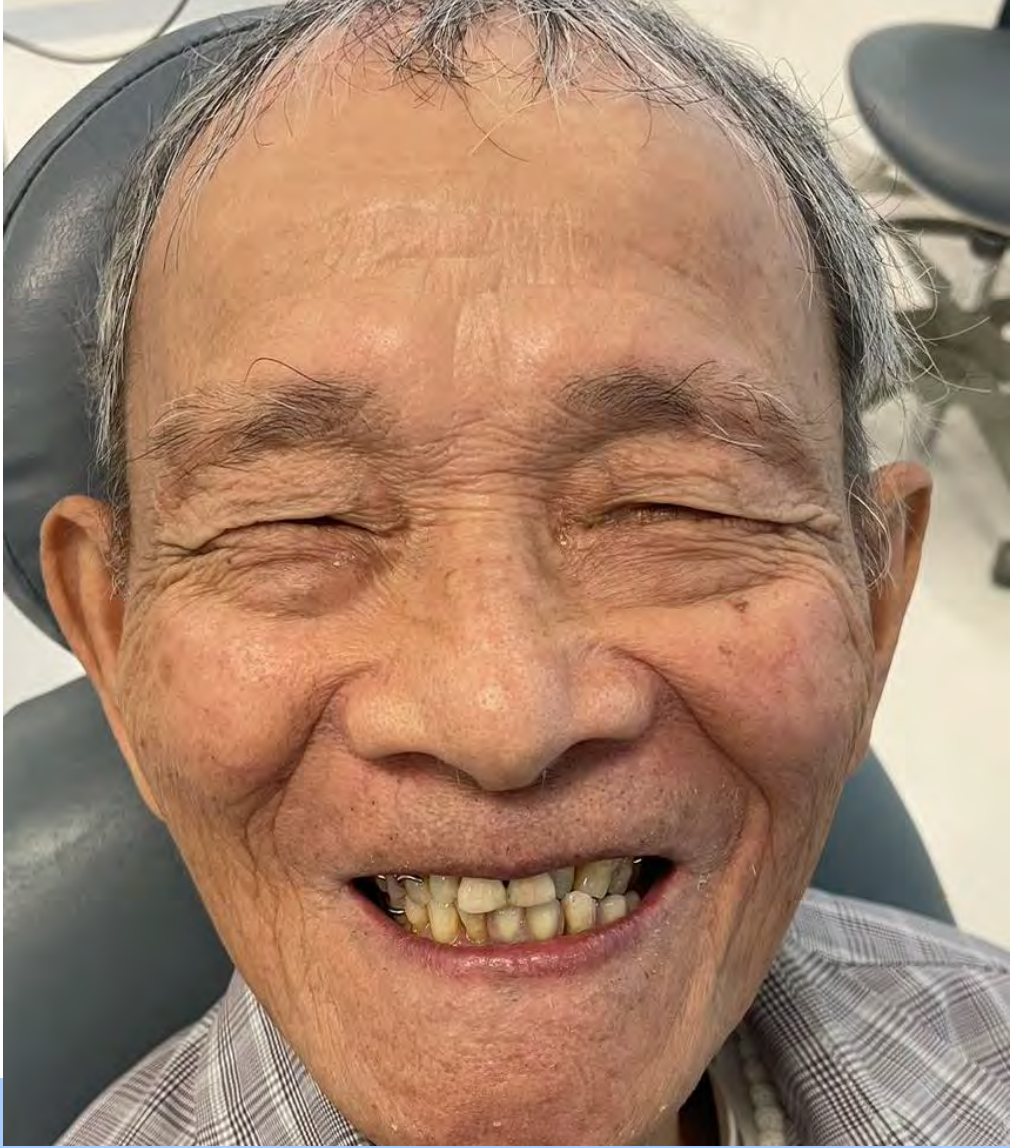4



**Before**



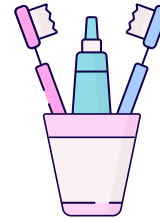
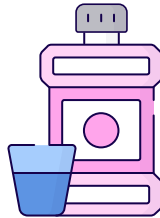
**After**



# Aftercare

## CAMBRA

CAMBRA products dispensed: CTX 4, High Fluoride tooth paste

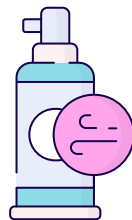

## OHI

Reinforce every appointment

## Medical+Diet Consult

To make sure GERD under control, no restorations are not damaged by acid



## Perio

Perio and denture recall

5

## Discussion



### One year before

I don't like to travel because I don't want to be a burden to my son on the trip. I am pretty old so I don't expect too much.

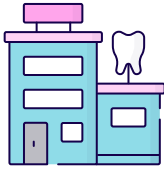### Now



I'm looking forward to traveling more these days. I can enjoy some new food with my sons. Plus, hanging out with my friends and doing Tai Chi puts a big grin on my face. They even asked me where I got my dentures from and I can see they are jealous. It's got me thinking, maybe I'll make it to 100 years old since I can eat whatever I want now. And getting my teeth back has definitely makes me feel a lot younger.

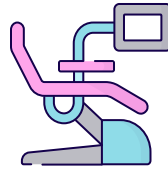

# Dugoni School Philosophy



## Head

Collaborate with faculties from multi-disciplinary department to provide comprehensive care



## Heart

Approach patient care with a humanistic perspective, treating individuals as we would want to be treated ourselves.



## Hands

Strive to deliver optimal care while demonstrating exceptional manual skills.

# Aknowledgement

**Dr. Eugene LaBarre**  
**Dr. Rebecca Moazzez**  
**Dr. Chi Tran**  
**Dr. Hussein Al-Wakeel**  
**Dr. Trang Nguyen**  
**Carlos Correa**



## Reference

1. AlShahrani MT, Haralur SB, Alqarni M. Restorative Rehabilitation of a Patient with Dental Erosion. *Case Rep Dent*. 2017;2017:9517486. doi: 10.1155/2017/9517486. Epub 2017 Jul 30. PMID: 28828189; PMCID: PMC5554566.
2. Benk I, Némethy M, Fábrián TK. Intrinsic erosio okozta foganyagveszteség helyreállítása porcelánborító koronákkal. Esetismertetés [Restoration of profound tooth damage caused by intrinsic erosion, with porcelain crowns. A case report]. *Fogorv Sz*. 2011 Sep;104(3):81-5. Hungarian. PMID: 22039713.
3. Tran C, LaBarre E, Landesman HM. A removable partial denture using an esthetically designed round-rest distal clasp on maxillary anterior abutment teeth: a clinical report. *J Prosthet Dent*. 2009 Nov;102(5):286-9. doi: 10.1016/S0022-3913(09)60174-8. PMID: 19853169.
4. Arigbede AO, Dosumu OO, Esan TA, Akeredolu PA. Acceptability of maxillary major connectors in removable partial dentures. *Afr Health Sci*. 2006 Jun;6(2):113-7. doi: 10.5555/afhs.2006.6.2.113. PMID: 16916303; PMCID: PMC1831977.
5. Featherstone JDB, Chaffee BW. The Evidence for Caries Management by Risk Assessment (CAMBRA®). *Adv Dent Res*. 2018 Feb;29(1):9-14. doi: 10.1177/0022034517736500. PMID: 29355423; PMCID: PMC5784484.
6. Yi WJ, Zhang JY, Kong WD, Mai AD, Duan JH. Clinical research on the relationship between the curve of Wilson and temporomandibular joint disorders. *J Stomatol Oral Maxillofac Surg*. 2023 Oct;124(5):101496. doi: 10.1016/j.ijorms.2023.101496. Epub 2023 May 12. PMID: 37182758.

# Thanks!

**Do you have any questions?**

by **Slidesgo**, including icons by **Flaticon**, and infographics & images by **Freepik**

