

Demystifying *Cracked-Tooth Syndrome*: An Evidence-Based Approach to Diagnosis and Treatment Planning



Siavash Ghadiri Zahrani

DDS Candidate, Class of 2024

University of the Pacific, Arthur A. Dugoni School of Dentistry



Patient Overview



Female	80 Years Old – ASA II	CC: “I started having pain when I eat after we extracted #30”
MHx	Chronic Lymphocytic Leukemia	Not being treated but monitored by hematologist
	Hypertension	Taking Amlodipine and Losartan daily
	Breast Cancer	Successfully treated in 1990s, but came back in summer 2023 (Grade 0) - Taking Tamoxifen daily
HCC/DH	VRF #30	Initial exam 3/15/23 - Pain in lower right due to VRF #30 EXT #30 on 5/19/23 Recall exam on 10/16/23 with current CC
SH / Allergies	Retired, drinks 1 glass of wine nightly - NKDA	



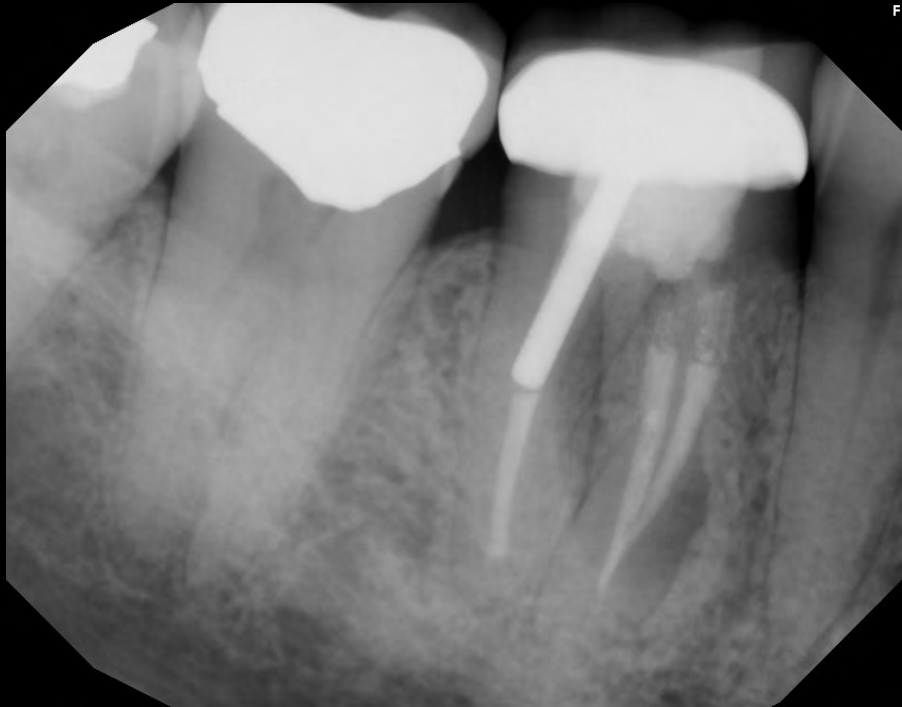
5/19/23 - EXT of #30 due to VRF

Initial RCT and crown done decades ago.

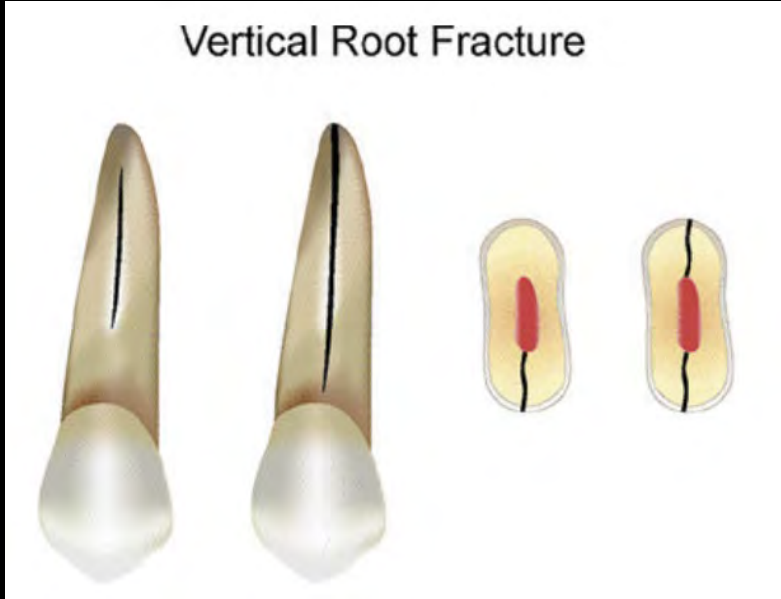
“J-shaped lesion” seen radiographically. Isolated 8mm pocket mid-lingual.¹

Dx: Previously treated with symptomatic apical periodontitis // Vertical Root Fracture (VRF)

Tx plan: Surgical EXT + bone graft for future implant



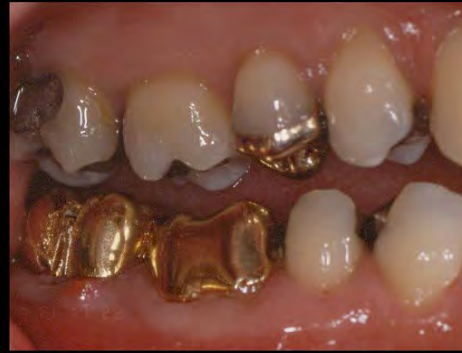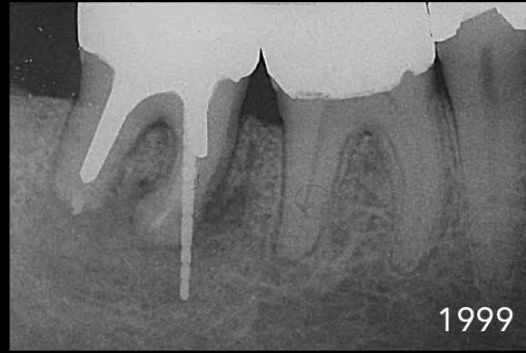
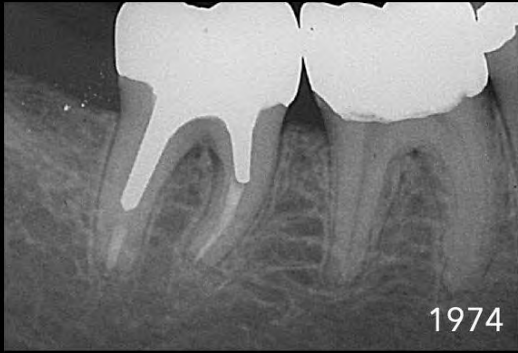Perio	BUCCAL	LINGUAL
30	334	382



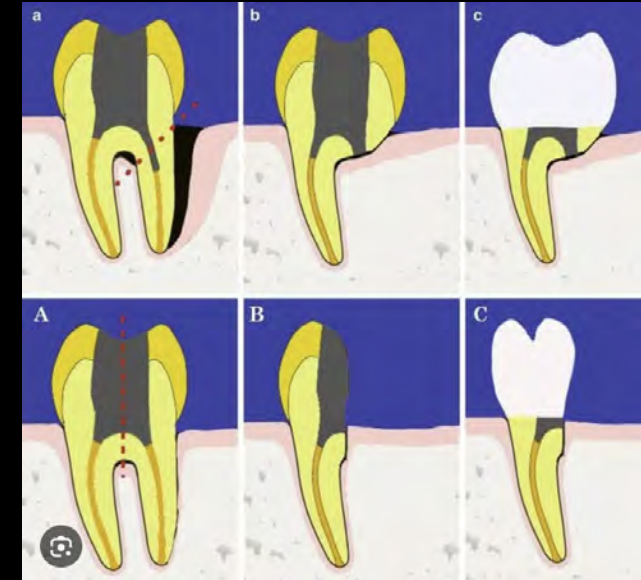
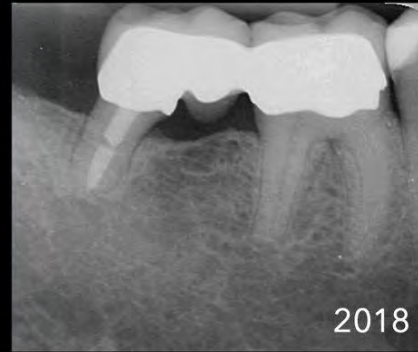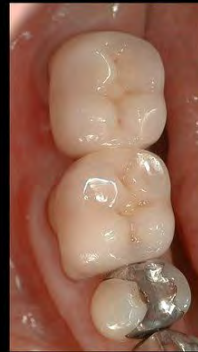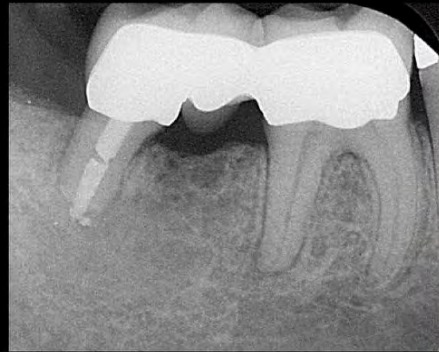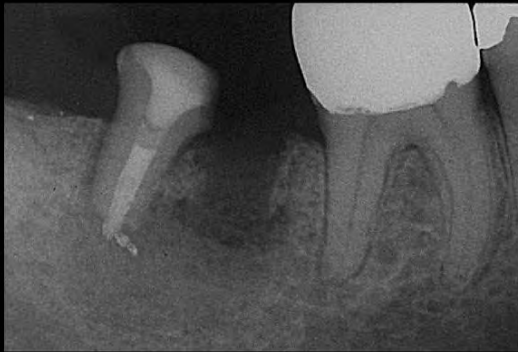1) Khasnis SA, Kidiyoor KH, Patil AB, Kenganal SB. Vertical root fractures and their management. J Conserv Dent. 2014 Mar;17(2):103-10. doi: 10.4103/0972-0707.128034. PMID: 24778502; PMCID: PMC4001262.

Krell KV, Cracked Teeth and Vertical Root Fractures: A New Look at a Growing Problem. American Association of Endodontists. 2022. <https://www.aae.org/specialty/wp-content/uploads/sites/2/2022/12/ecfe-2022-edition-FINAL.pdf>.

Alternative Tx for VRF



ROOT AMPUTATION → 92% survival over 12 years¹
HEMISECTION → 79 to 91% survival over seven to 30 years²



Credit: Dr. Marga Ree DDS, MSc

ENDO PRAKTIJK

Another reason to consider keeping half of a multi-rooted tooth:

Patients experienced four times as many appointments when agreeing to a single tooth implant versus patients having non-surgical root canal treatment and a crown with over twice the expense.³

→ Fewer complications than implants, less chair time, fewer appointments, less costly to patient, but no longer “in vogue”

1) Basten CH, Ammons WF Jr, Persson R. Long-term evaluation of root-resected molars: a retrospective study. Int J Periodontics Restorative Dent. 1996 Jun;16(3):206-19. PMID: 9084307
 2) Derks H, Westheide D, Pfefferte T, Eickholz P, Dannewitz B. Retention of molars after root-resective therapy: a retrospective evaluation of up to 30 years. Clin Oral Investig. 2018 Apr;22(3):1327-1335. doi: 10.1007/s00784-017-2220-1. Epub 2017 Oct 7. PMID: 28988369
 3) Vahdati SA, Torabinejad M, Handysides R, Lozada J. A Retrospective Comparison of Outcome in Patients Who Received Both Nonsurgical Root Canal Treatment and Single-tooth Implants. J Endod. 2019 Feb;45(2):99-103. doi: 10.1016/j.joen.2018.10.018. PMID: 30711185



10/16/23 - Recall Exam, *Cracked Tooth Syndrome*

CC: **Bilateral pain in lower posterior teeth when eating**, which appeared shortly after EXT #30. Pain is unilateral and stops when chewing on opposite side (see-saw analogy)

Assumption-Based Diagnosis	Evidence-Based Diagnosis
<ul style="list-style-type: none"> Immediate assumption for “pain when chewing” is likely symptomatic apical periodontitis, or some form of “endo problem” Immediate recommendation: RCT + Full coverage crowns 	<ul style="list-style-type: none"> Thermal testing normal Percussion testing normal No isolated deep pockets Tooth slooth /cotton roll revealed pain on release and compression Full-coverage crown #17, 18, 32 WITHOUT RCT

Only reproducible symptom = painful bite

DIAGNOSIS: Normal pulp, normal apical tissue, “CRACKED TOOTH”^{1, 2}

Perio	Buccal	Lingual	Endo	COLD	PERCUSSION	PALPATION
17	323	543	*17	WNL	WNL	WNL
18	323	324	*18	WNL	WNL	WNL
32	334	445	*32	WNL	WNL	WNL
			1, 2	WNL	WNL	WNL
			15, 16	WNL	WNL	WNL
			20	WNL	WNL	WNL
			29	WNL	WNL	WNL

1) Lubisich EB, Hilton TJ, Ferracane J; Northwest Precedent. Cracked teeth: a review of the literature. J Esthet Restor Dent. 2010 Jun;22(3):158-67. doi: 10.1111/j.1708-8240.2010.00330.x. PMID: 20590967; PMCID: PMC3870147.

2) Mathew S, Thangavel B, Mathew CA, Kailasam S, Kumaravadivel K, Das A. Diagnosis of cracked tooth syndrome. J Pharm Bioallied Sci. 2012 Aug;4(Suppl 2):S242-4. doi: 10.4103/0975-7406.100219. PMID: 23066261; PMCID: PMC3467890



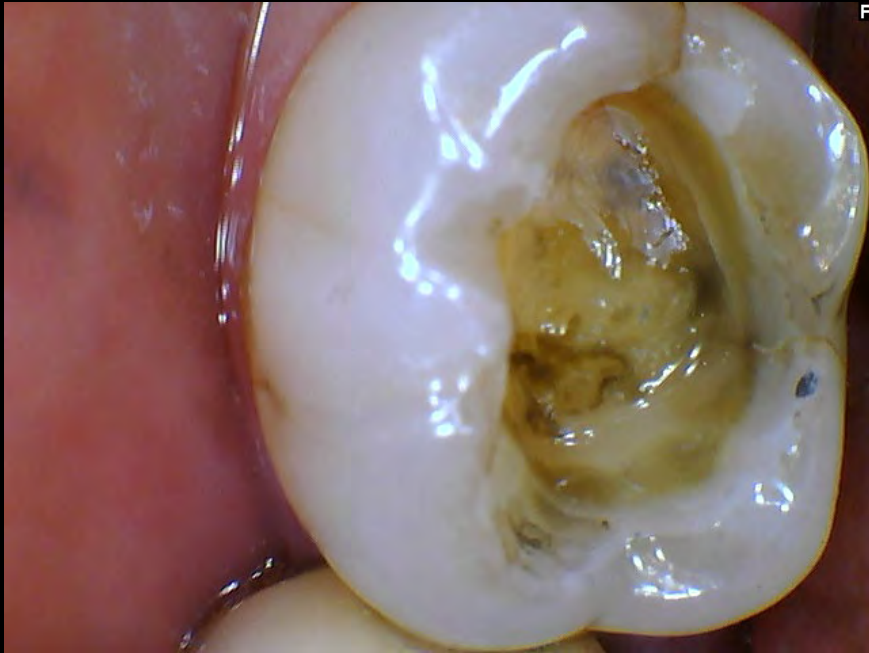AAE's Clinical Testing Recommendations

- **Soft tissue exam** for localized swelling or sinus tract(s) ✓
- **Percussion** ✓
- **Palpation** ✓
- **Biting tests** (each cusp should be tested) ✓
- **Vitality tests** (Electric pulp testing and cold testing) ✓
- **Periodontal probing** (flexible plastic probes) ✓
- **Restoration removal** (if necessary for complete visualization) ✓
- **Transillumination** (to look for disruptions in light transmission which are common in cracked teeth) ✗
- **Dye Staining** (either before or after restoration removal) ✗
- **Surgical Assessment** ✗
- **Radiographic exam** which includes both periapical films (PA) and Cone Beam Computerized Tomography (CBCT) should be performed routinely ✓

Transillumination and **dye staining** were not attempted as the cracks in this case were clearly visible.

Surgical assessment (flap surgery) was not attempted due to anatomic difficulty and CBCT findings not indicating the presence of sub-cortical extension of cracks.

11/18/23 – Replacement of Amalgam with Bonded Core Build-Up Material (PhotoCore)

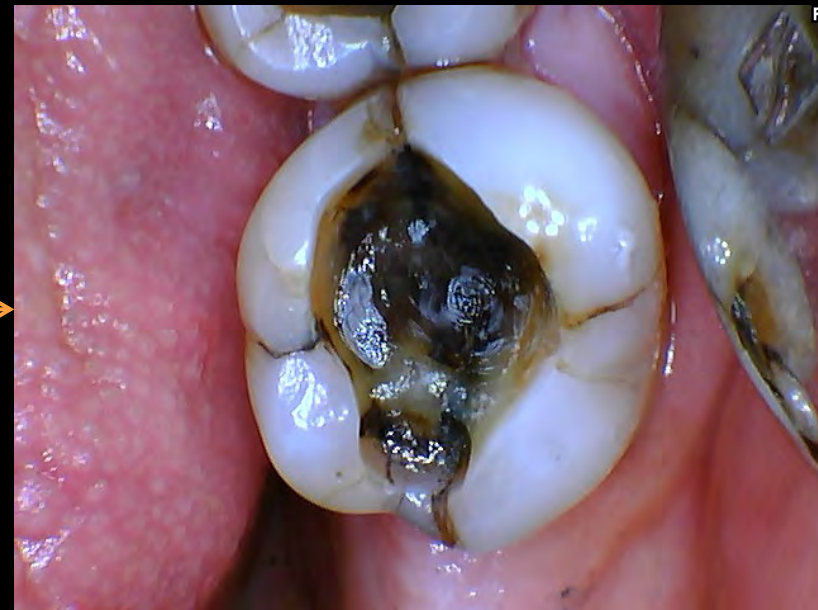
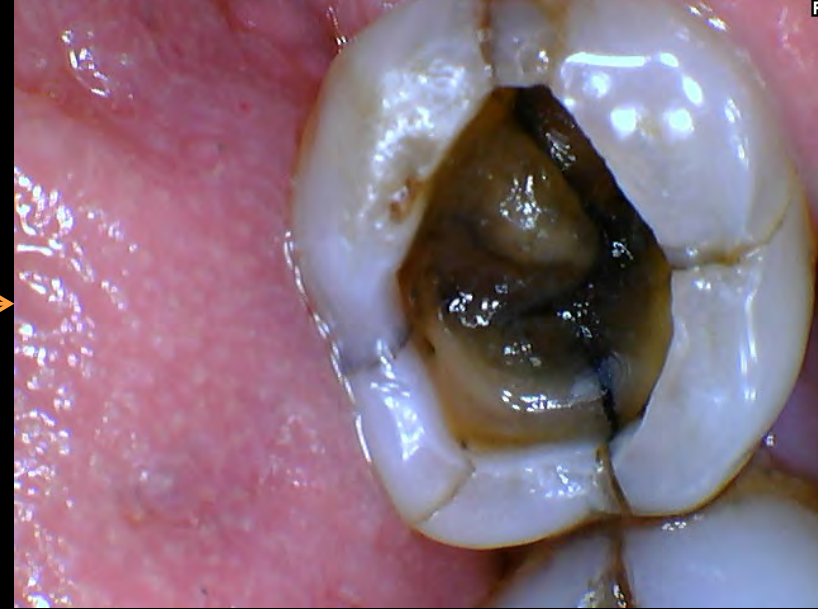
Distal marginal ridge crack line and a lingual wall crack line can be seen visibly in #32

#17

#18

#32



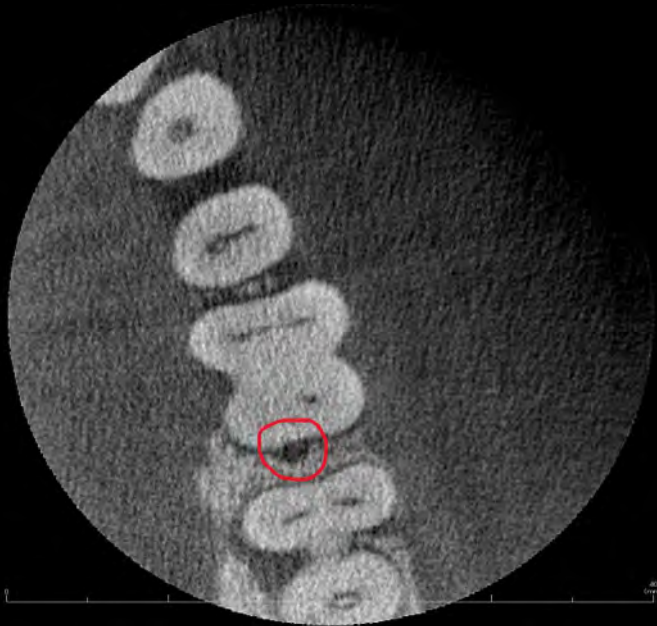

CBCT Assessment

1/17/24 – Presented for final impression #17, 18 **but #18 was still symptomatic**
CBCT taken to assess extent of cracks

→ **Cracks that extend to the pulp chamber floor or below may have a “hopeless” prognosis, and primary Tx is EXT. ¹**

CBCT revealed no obvious cracks or pathologies, recommended to proceed with FVC up until final cementation, and to reassess symptoms after a month. Refined #17, 18 and temporized with splinted integrity.



Conclusions: Patterns of bone loss on CBCT imaging can likely differentiate between cracked teeth and teeth with VRF. The presence of an angular defect may suggest the presence of a crack in the tooth before intervention. J-shaped defects, deep probing (>6 mm), and loss of the cortical plate are likely suggestive of VRF.

How to diagnose cracks from CBCT? ²

- 1) Louis H. Berman, Sergio Kuttler, Fracture Necrosis: Diagnosis, Prognosis Assessment, and Treatment Recommendations, Journal of Endodontics, Volume 36, Issue 3, 2010, Pages 442-446, ISSN 0099-2399, <https://doi.org/10.1016/j.joen.2009.12.018>
- 2) Alaugaily I, Azim AA. CBCT Patterns of Bone Loss and Clinical Predictors for the Diagnosis of Cracked Teeth and Teeth with Vertical Root Fracture. J Endod. 2022 Sep;48(9):1100-1106. doi: 10.1016/j.joen.2022.06.004. Epub 2022 Jun 14. PMID: 35714728

CBCT Assessment



IMPRESSIONS

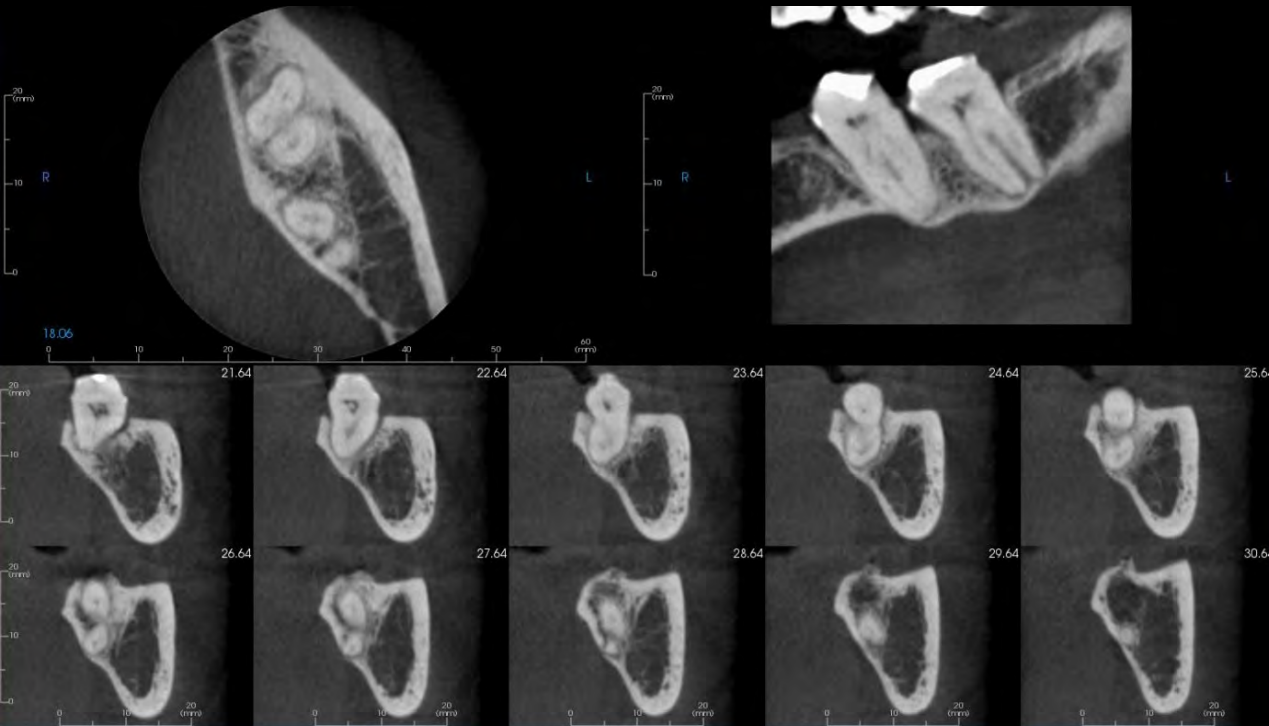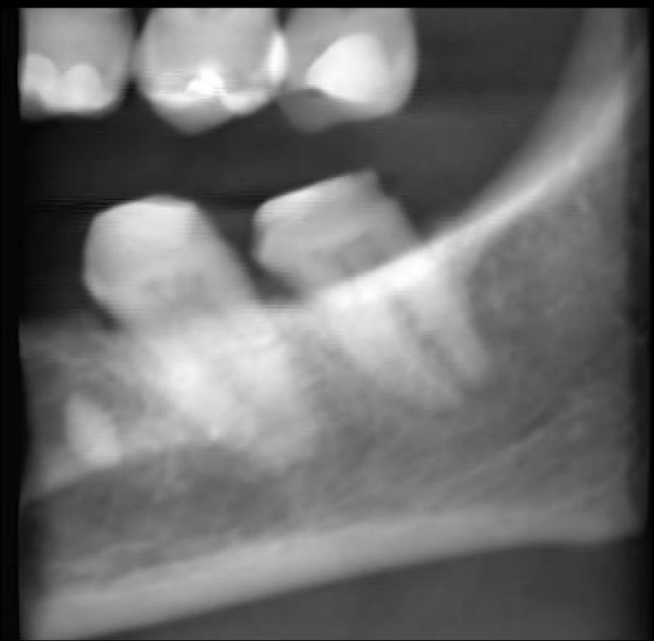
Teeth #17 and 18: The appearance of apical periodontal ligament space widening associated with the roots of #17 and 18 suggest anatomic variants of the periodontal ligament spaces within cortical bone; however, clinical correlation is recommended for further evaluation and to rule out the possibility of periapical rarefying osteitis associated with the teeth. The bulky appearance of the roots of #18 are most compatible with the effects of hypercementosis.

Thank you for requesting this consultation regarding your patient.

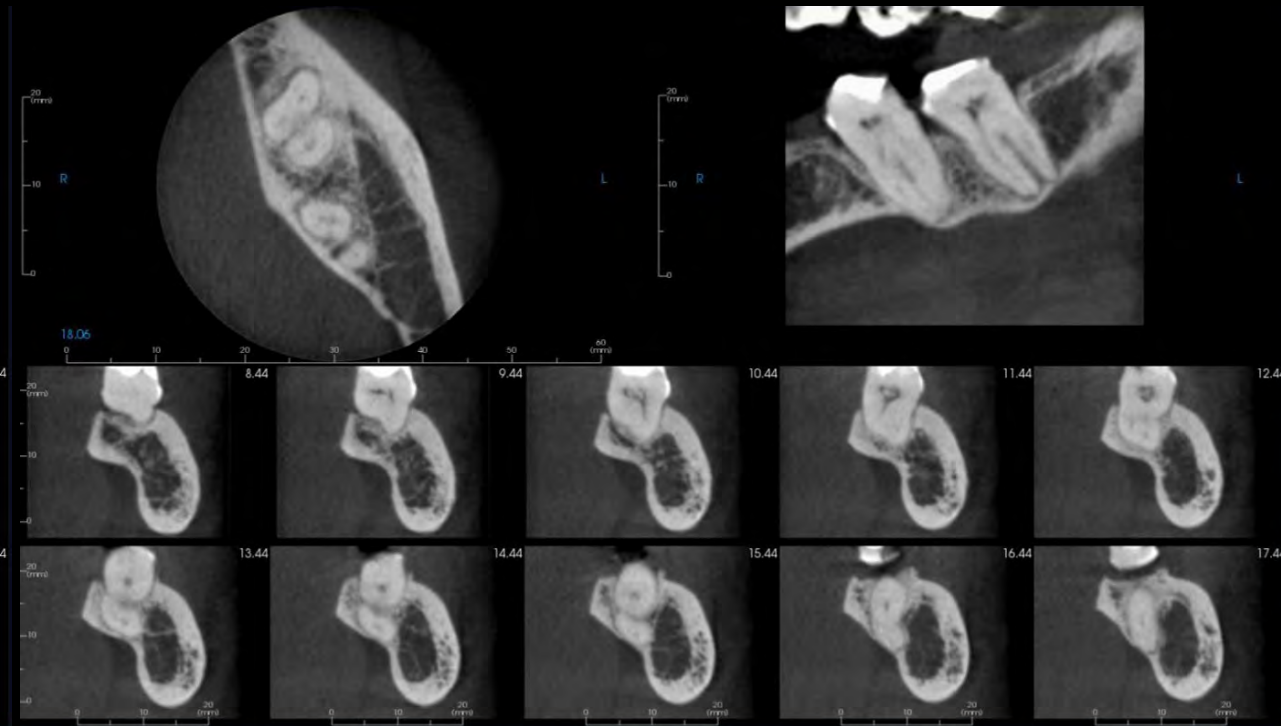
Jalal Bukhari

Dr. Jalal Bukhari
Oral and Maxillofacial Radiologist

No patterns of apical pathologies or bone loss indicative of root fracture were observed



Multiplanar reconstruction of #17.



Multiplanar reconstruction of #18.



Etiology and Clinical Significance

Ricucci et al., 2015

Etiologies of cracked teeth include

- Malocclusion
- Bruxism
- Parafunctional habits
- “Wedging events”
- Repetitive occlusal forces
- Physical trauma
- Resorption
- Caries
- Weakened teeth
- Iatrogenic dentistry

As these early cracks develop, bacteria and biofilms can form, eventually progressing towards the pulp and resulting in pulpal necrosis

“Cracks are ALWAYS colonized with bacterial biofilms.

The pulp tissue response varies according to the location, direction, and extent of the crack.”

Therefore, RCT *may or may not* be indicated!

ONLY if crack has resulted in bacterial contamination of pulpal tissue should RCT be initiated.

Etiology and Clinical Significance

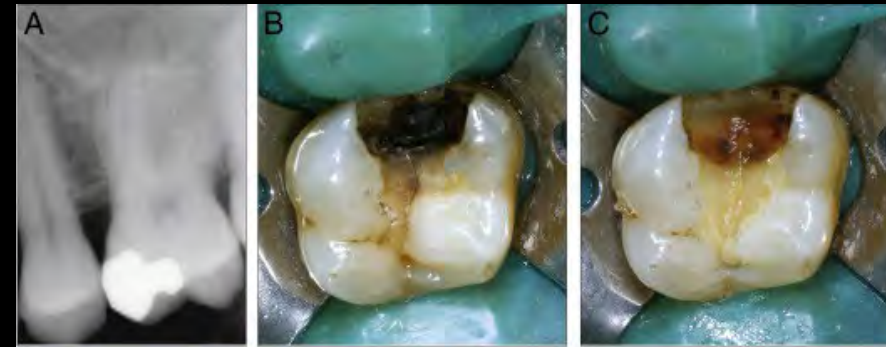
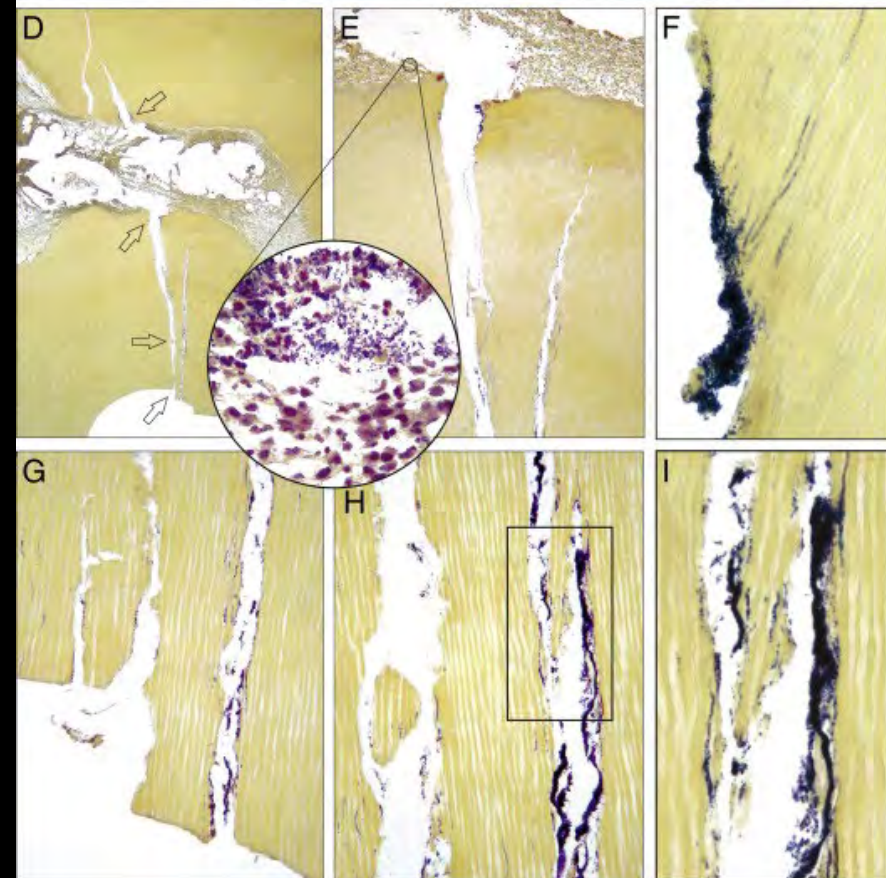


Figure 4. The case of a 54-year-old man with severe spontaneous pain caused by the maxillary left first molar (#6, Table 1). Pain was exacerbated by chewing. Thermal and electric tests gave exaggerated responses. The tooth was tender to percussion. (A) The radiograph showed a mesioocclusal amalgam restoration and an apical radiolucency on the palatal root. (B) After anesthesia and rubber dam isolation, the restorative materials were removed. Caries was present on the cavity floor. (C) After caries removal, a mesiodistal crack line was evident. Treatment possibilities and prognosis were thoroughly explained to the patient, and extraction was requested. The tooth was processed for histology, and sections were taken on a buccolingual plane. (D) An overview of the pulp chamber. The overlying dentin is crossed by 2 crack lines, one of which can be followed uninterruptedly from the cavity floor to the pulp chamber. Additional crack lines affected the dentin of the pulp chamber floor. The tissue in the pulp chamber appears unstructured (Taylor's modified Brown and Brenn, original magnification $\times 16$). (E) Detail of the area where the fracture reaches the pulp indicated by the second *upper arrow* in D (original magnification $\times 100$). (*Inset*) Bacterial aggregates faced with PMNs (original magnification $\times 630$). (F) High-power magnification from the right wall of the crack in the pulp chamber floor indicated by the *upper arrow* in D (original magnification $\times 400$). (G) Magnification of the origin of the crack lines on the cavity floor indicated by the *lower arrow* in D. Note the amount of bacteria penetrated both in the fractures and in dentinal tubules (original magnification $\times 200$). (H) High-power magnification of the area indicated by the second *lower arrow* in D. Crack lines and the adjacent tubules are congested with bacteria (original magnification $\times 200$). (I) High-power magnification of the area demarcated by the rectangle in H (original magnification $\times 400$).



Ricucci et al., 2015

“Cracks are ALWAYS colonized with bacterial biofilms.

The pulp tissue response varies according to the location, direction, and extent of the crack.”

Therefore, RCT may or may not be indicated!

ONLY if crack has resulted in bacterial contamination of pulpal tissue should RCT be considered.

Etiology and Clinical Significance



Ricucci et al., 2015

“Cracks are ALWAYS colonized with bacterial biofilms.

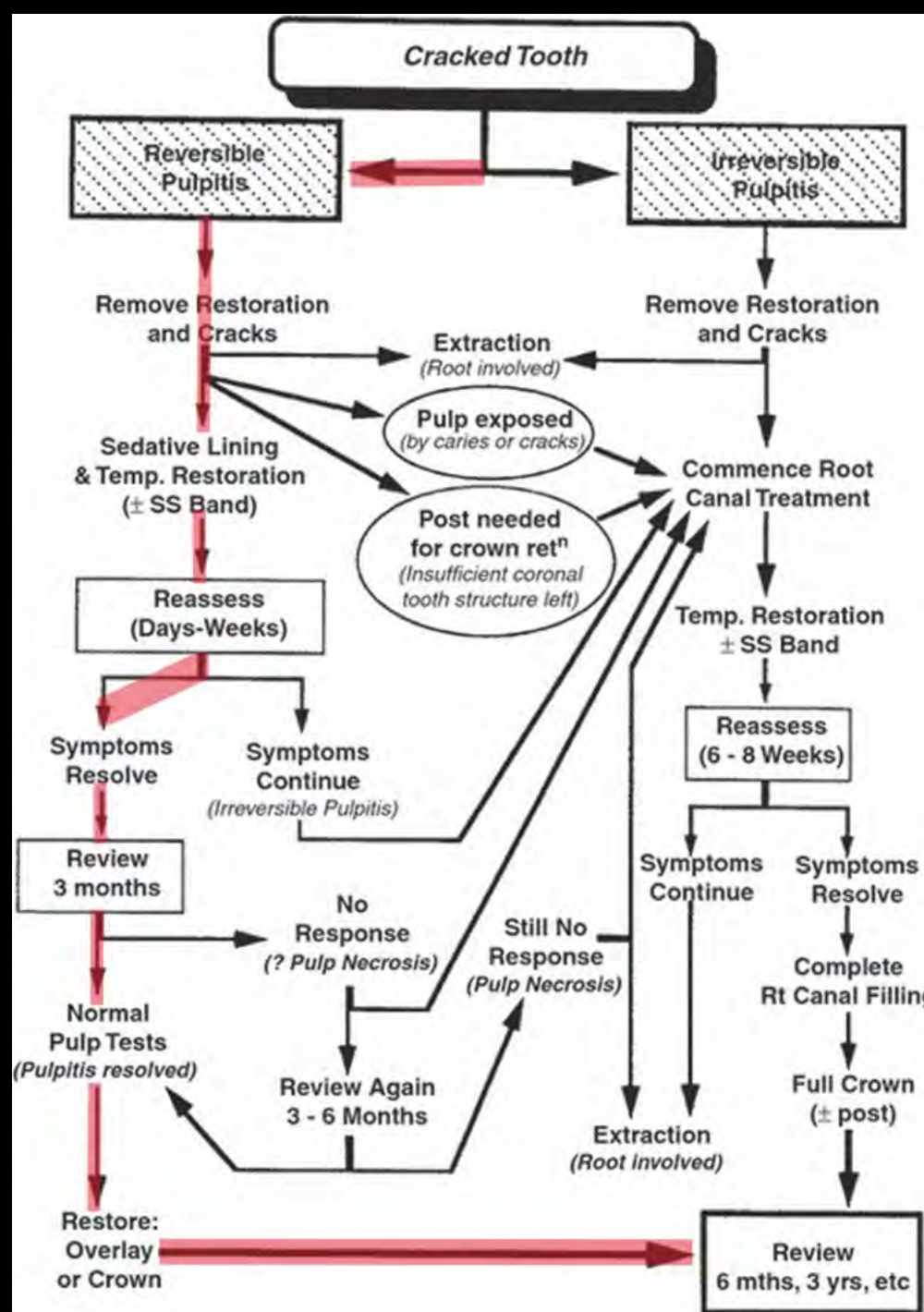
The pulp tissue response varies according to the location, direction, and extent of the crack.”

Therefore, RCT *may or may not* be indicated!

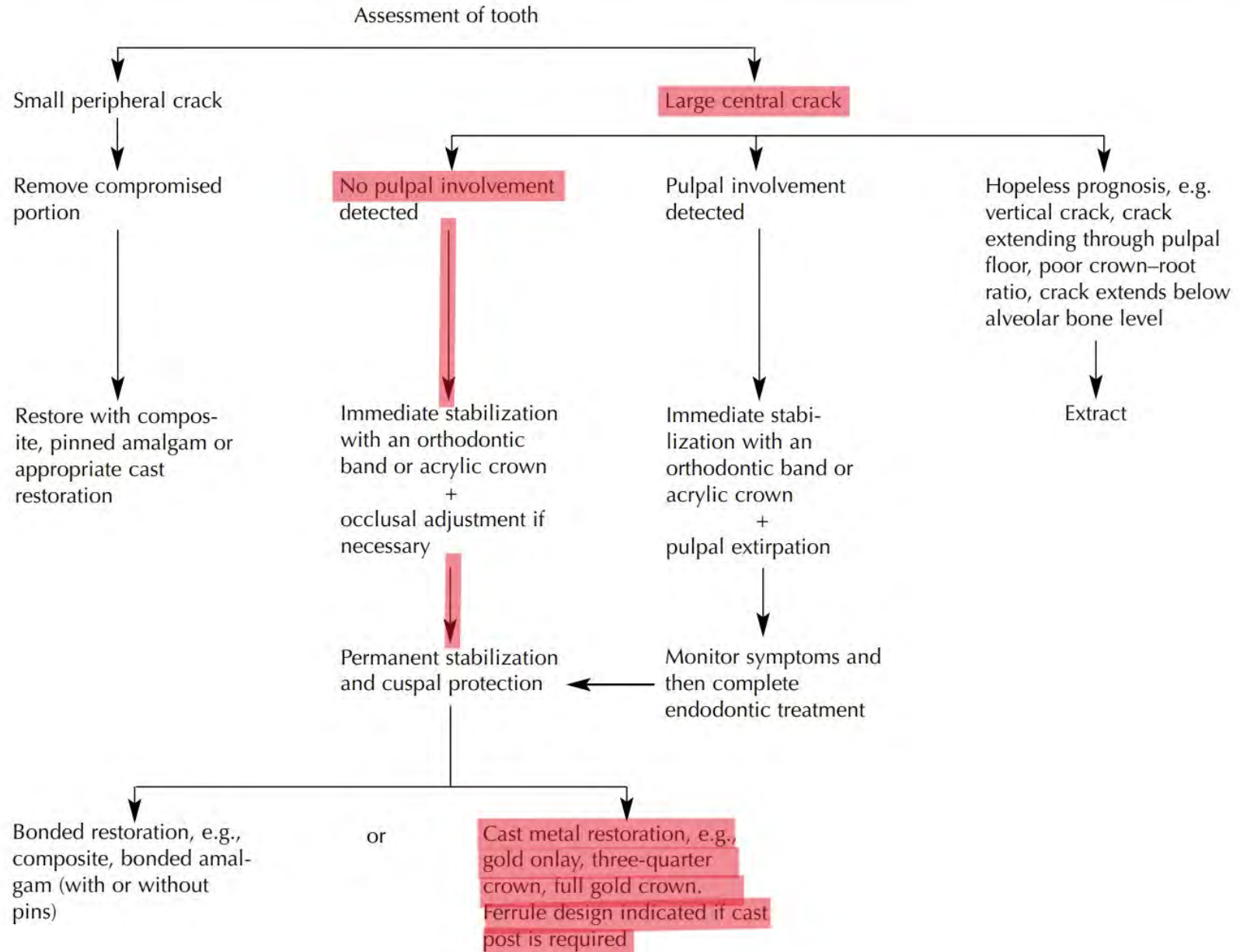
ONLY if crack has resulted in bacterial contamination of pulpal tissue should RCT be considered.



Decision Making



Abbott, P. and Leow, N. (2009), Predictable management of cracked teeth with reversible pulpitis. Australian Dental Journal, 54: 306-315. <https://doi.org/10.1111/j.1834-7819.2009.01155.x>

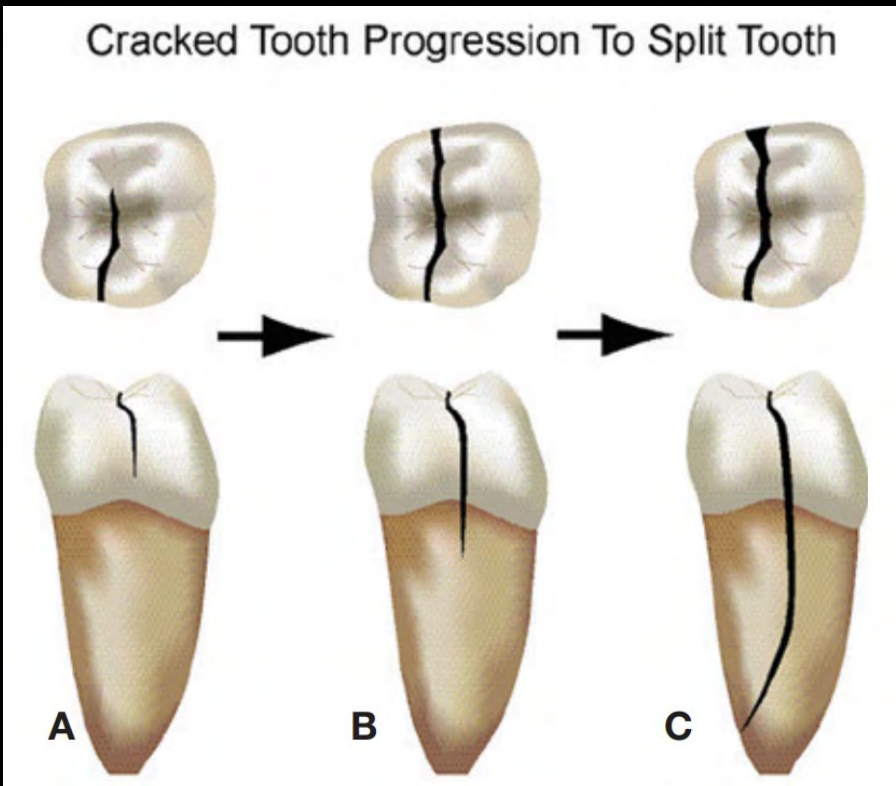
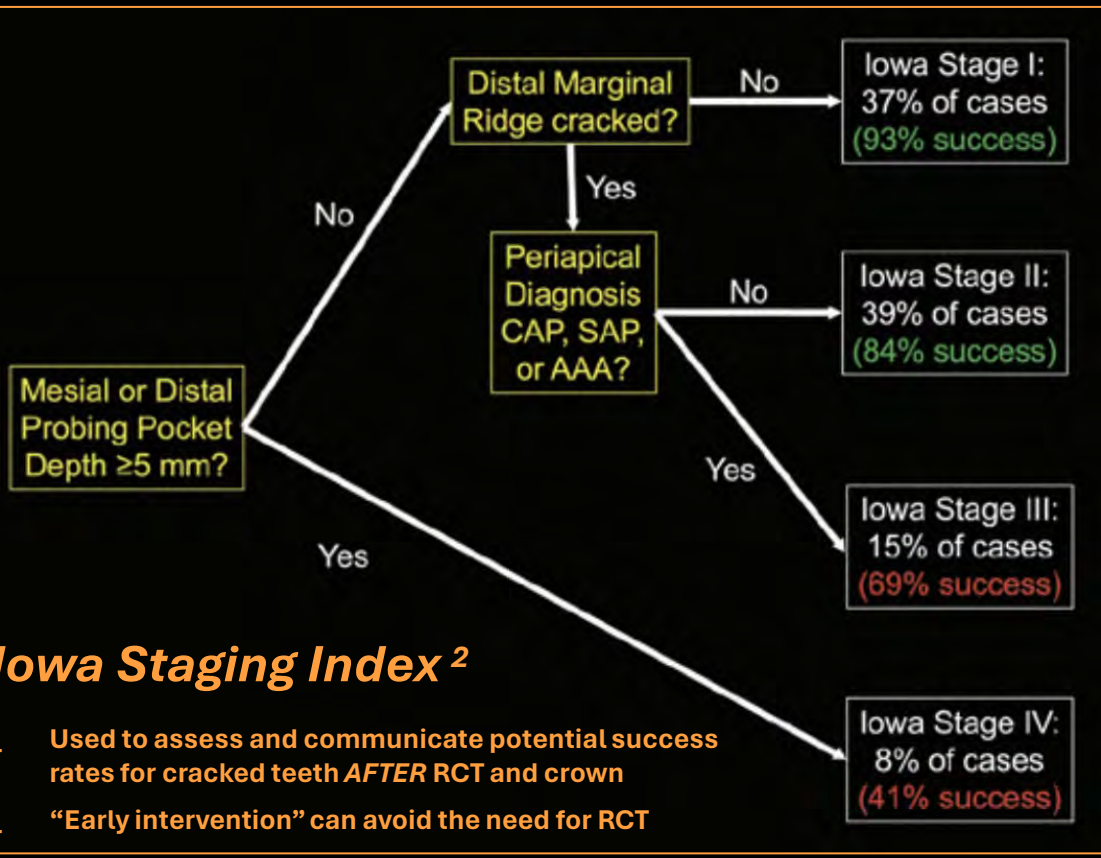


Decision Making



Early Intervention!

98% success rate over 11 years with early intervention for cracked teeth, success not affected by RCT unless clinically indicated ¹



Cracked teeth with reversible pulpitis and normal apices that were immediately crowned had an 80% chance of never needing root canal treatment. ⁴

“Cracks when left untreated, can propagate into fractures resulting in catastrophic failures and tooth loss, such as in the incidence of a split tooth.” ³

1) Toubes, Kênia & Quadros Tonelli, Stéphanie & Côrtes, Maria & Soares, Carlos & Bruzanga, Fábio & V Soares, Rodrigo & Silveira, Frank. (2021). The Correlation of Crack Lines and Definitive Restorations with the Survival and Success Rates of Cracked Teeth: A Long-term Retrospective Clinical Study. *Journal of Endodontics*. 48. 10.1016/j.joen.2021.10.010

2) Krell KV, Caplan DJ. 12-month Success of Cracked Teeth Treated with Orthograde Root Canal Treatment. *J Endod*. 2018 Apr;44(4):543-548. doi: 10.1016/j.joen.2017.12.025. Epub 2018 Feb 21. PMID: 29429822

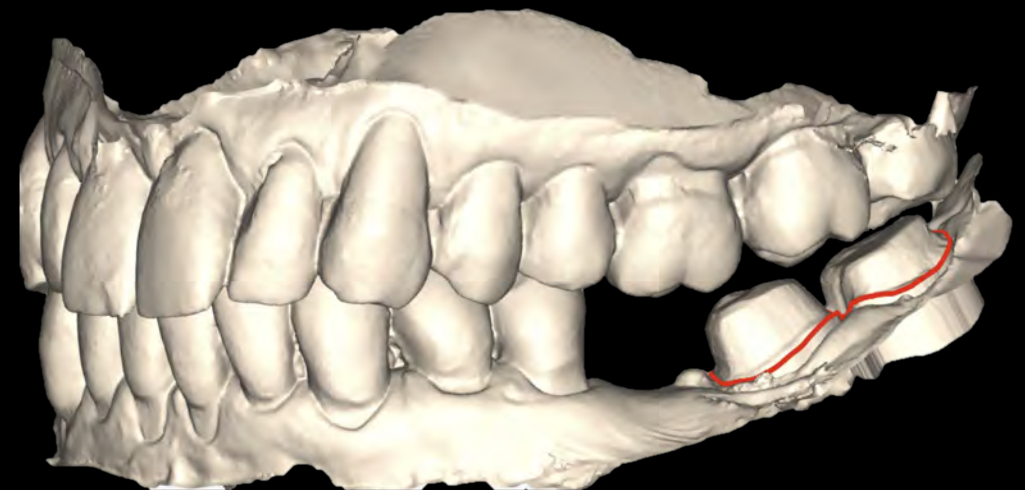
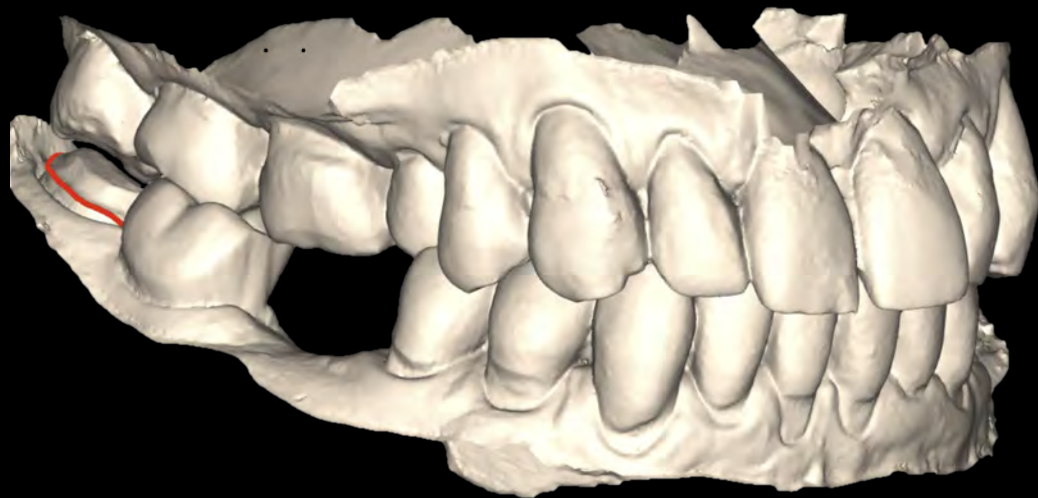
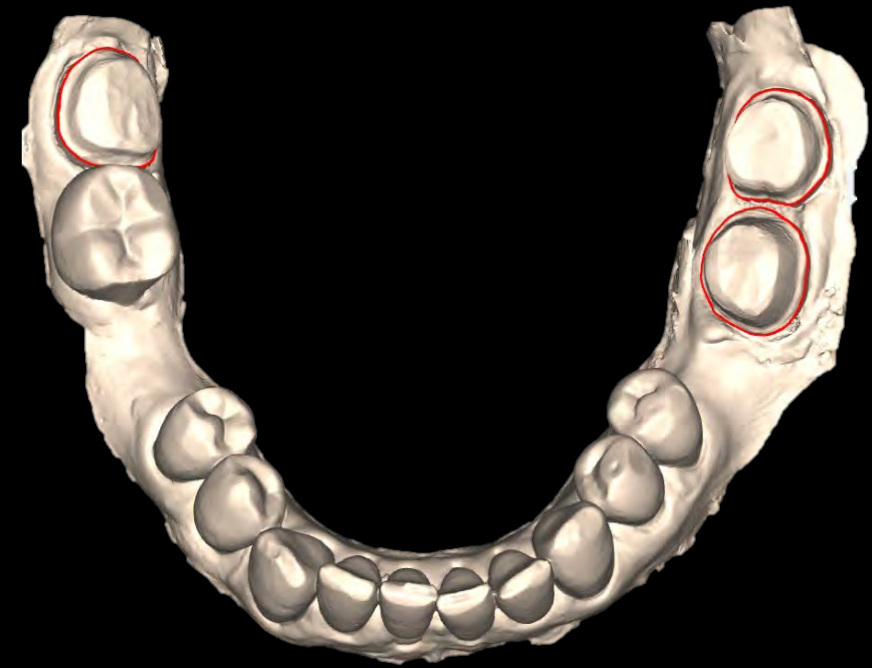3) Rivera, R.M.a.W., R.E., Cracking the cracked tooth code: detection and treatment of various longitudinal tooth fractures. *Colleagues for Excellence*. Chicago, American Association of Endodontists, 2008

4) Krell, K.V. and E.M. Rivera, A six year evaluation of cracked teeth diagnosed with reversible pulpitis: treatment and prognosis. *J Endod*, 2007. 33.

2/16/24 – Final Impression



Scanned via iTero
Notice posterior cross-bite



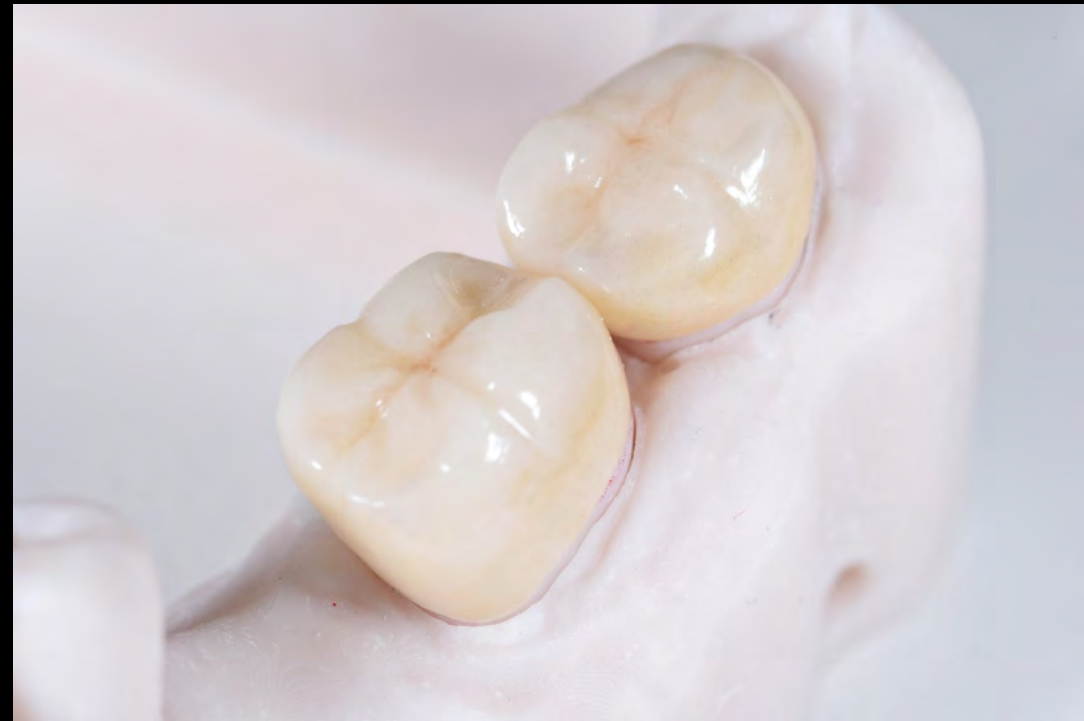
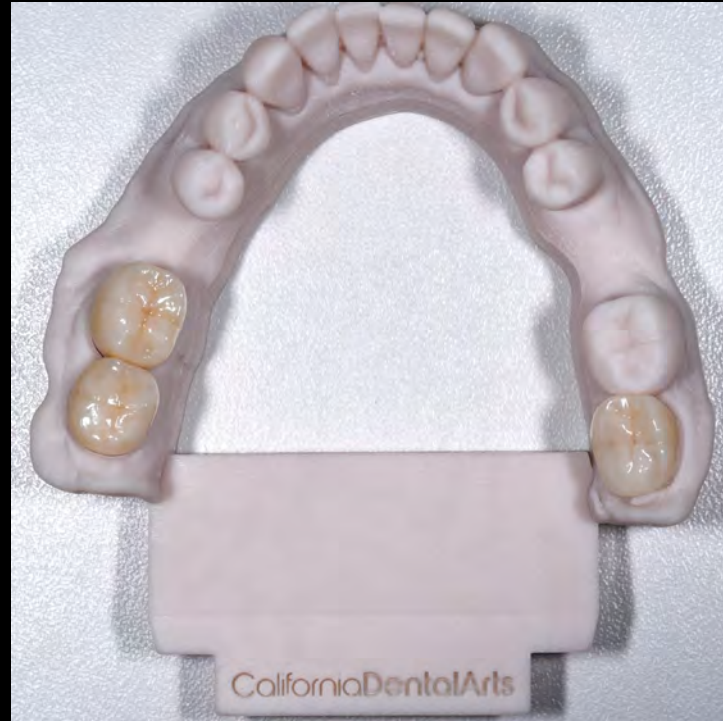
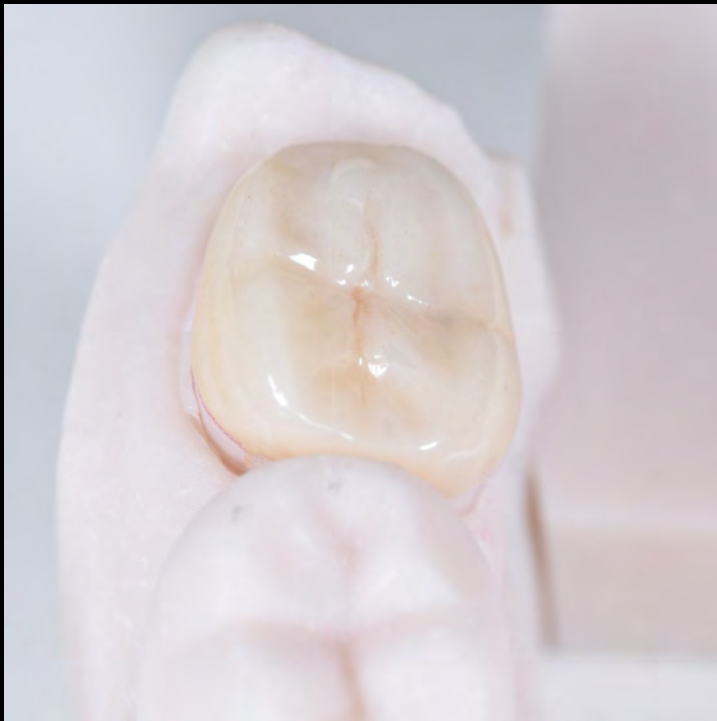3/15/24 - CIMOE

All teeth tested vital and asymptomatic.

Patient expressed complete resolution of symptoms.

Cemented with Nexus 3 bonded resin cement due to short clinical crown preparations of wisdom teeth.



Assessment of Remaining Dentition

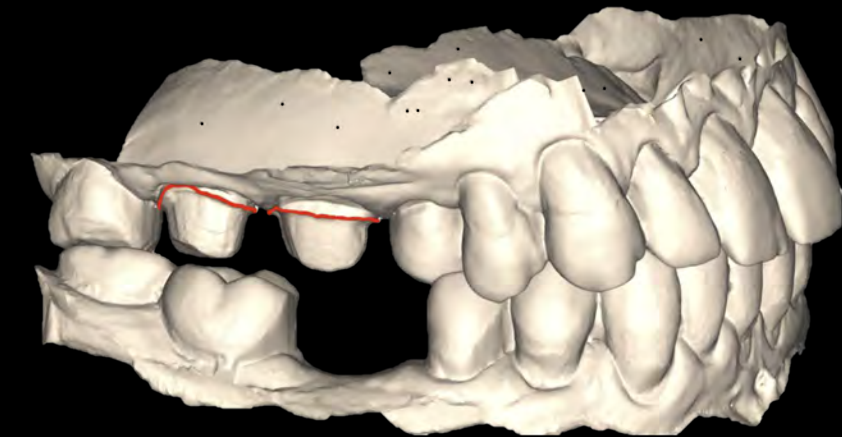
#2 fractured distal marginal ridge, BL-MD crack lines, large amalgam restoration

#3 BL-MD crack lines, large amalgam restoration

Tx plan: **#2, #3 FVC**

Rationale: Asymptomatic... FOR NOW

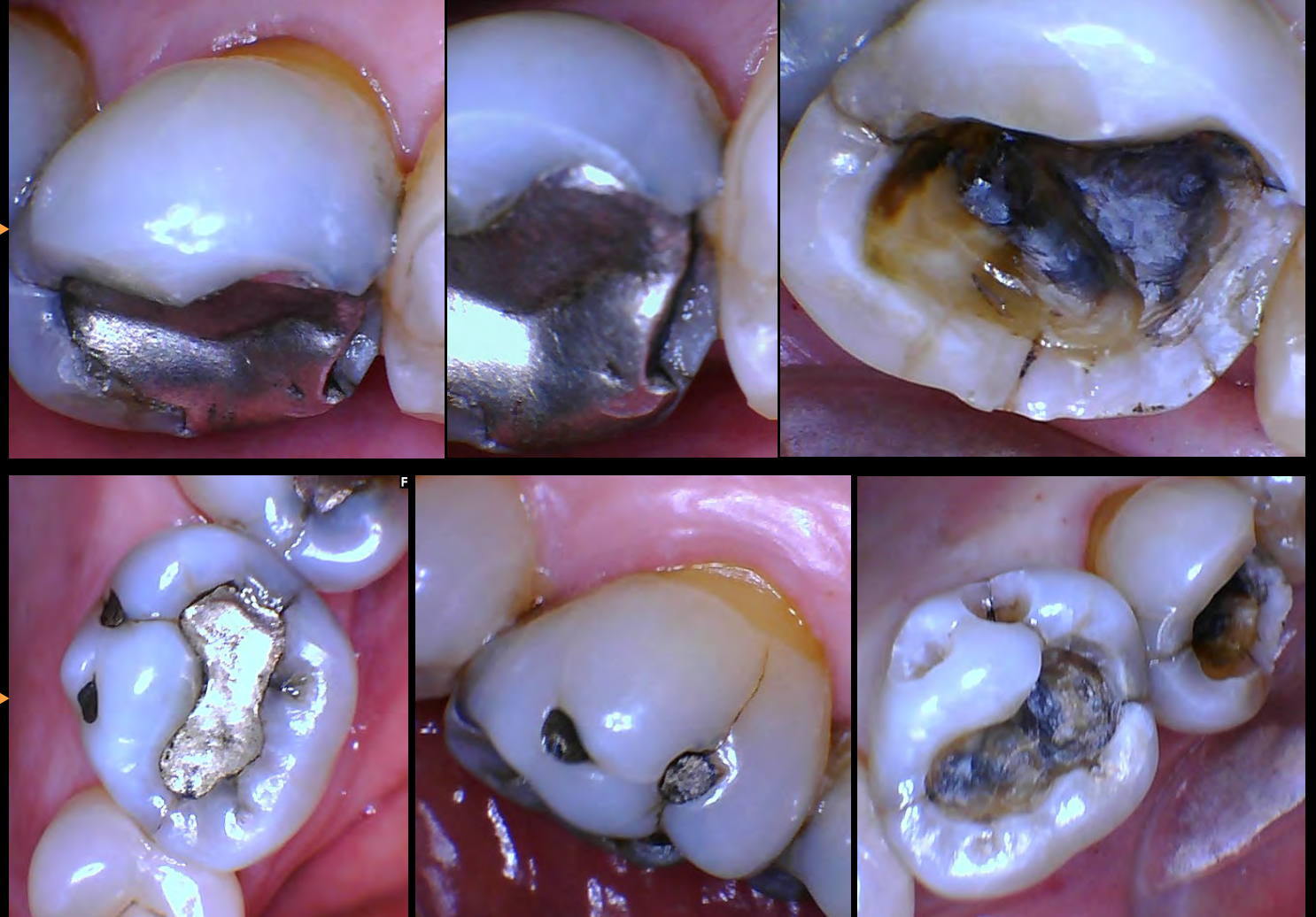
Early Intervention!



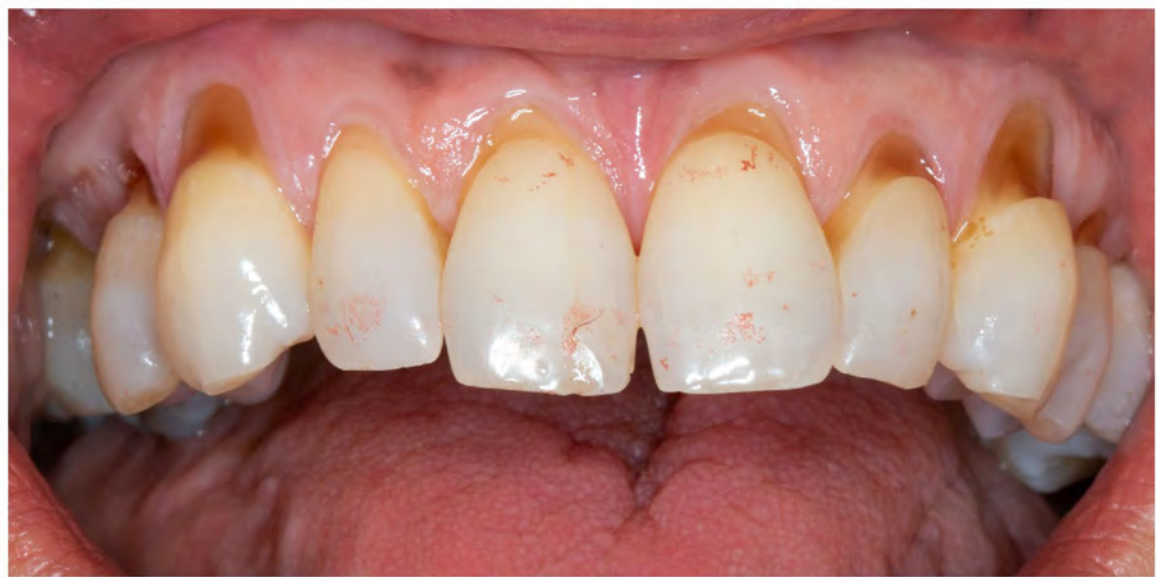Final impression scanned via iTero

#2

#3



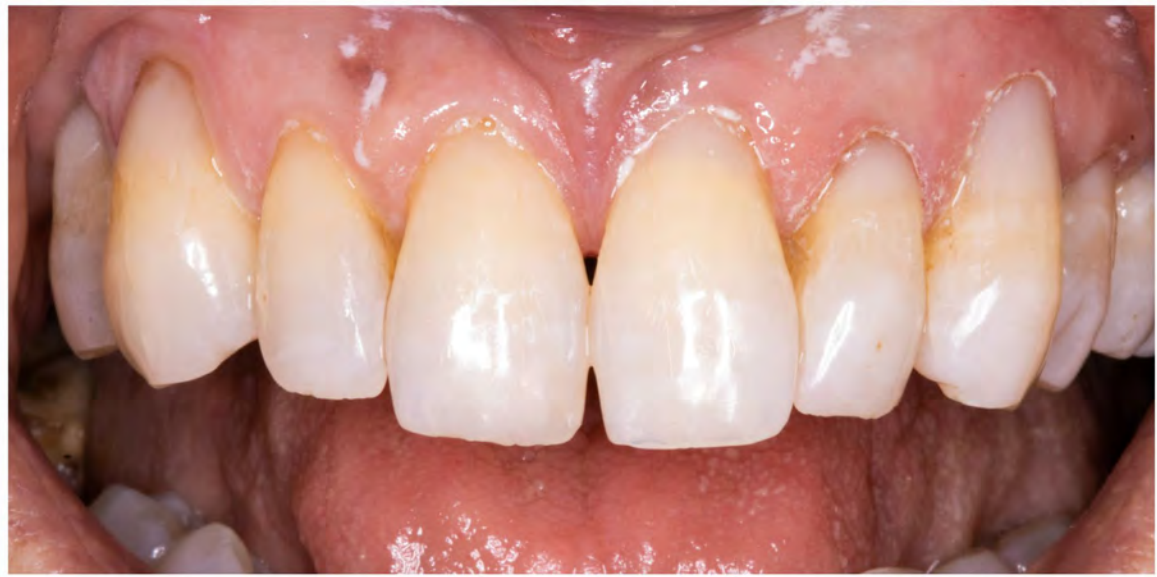Re-assessment & Reflection



ABFRACTIONS seen at initial ODTP

→ Evidence of heavy occlusion

→ Composite restorations were made in June 2023 to address CC of wanting to “fill in the gaps above my teeth”



Occlusal night guard was recommended to help counteract heavy occlusion and extend longevity of dentition and restorations, but patient denied recommendation at that time.

Perhaps with more effective patient education and by recognizing the ramifications of cracked teeth at initial appointment, the night guard could have delayed the symptoms from her cracked molars.

Abfraction: A V-shaped loss of hard tooth structure caused by biomechanical loading forces such as from flexure and/or chemical fatigue degradation of enamel and/or dentin at some location distant from the actual point of loading.



Confusion around Cracked Teeth

Common Misconceptions	Incorrect Action	Correction
<ul style="list-style-type: none">• Patient will become upset if RCT is needed AFTER delivery of final crown due to structural weakening	<ul style="list-style-type: none">• “Pre-emptive” RCT is done to avoid patient backlash and to salvage reputation and artificial crown	<p>95.3% success rate for RCT through intact FVC¹</p> <ul style="list-style-type: none">• Prioritizes NATURAL TOOTH over artificial crown
<ul style="list-style-type: none">• Anecdotal evidence of past patients' symptoms resolving after RCT and crown	<ul style="list-style-type: none">• “One size fits all” approach to treatment• Automatic Tx of RCT+crown for any painful bite	<ul style="list-style-type: none">• Thorough diagnostic testing• Evidence-based diagnosis• Evidence-based treatment

TAKEAWAYS

- RCT THROUGH CROWN DOESN'T AFFECT ITS LONGEVITY
- PATIENT EDUCATION AND PROPER DIAGNOSIS ARE KEY
- **DON'T DO RCT “JUST IN CASE”**



Rising Number of Cases

J Endod. 2022 Oct; 48(10): 1241–1247.

PMCID: PMC9273286

Published online 2022 Jul 12. doi: [10.1016/j.joen.2022.07.002](https://doi.org/10.1016/j.joen.2022.07.002)

PMID: [35835260](https://pubmed.ncbi.nlm.nih.gov/35835260/)

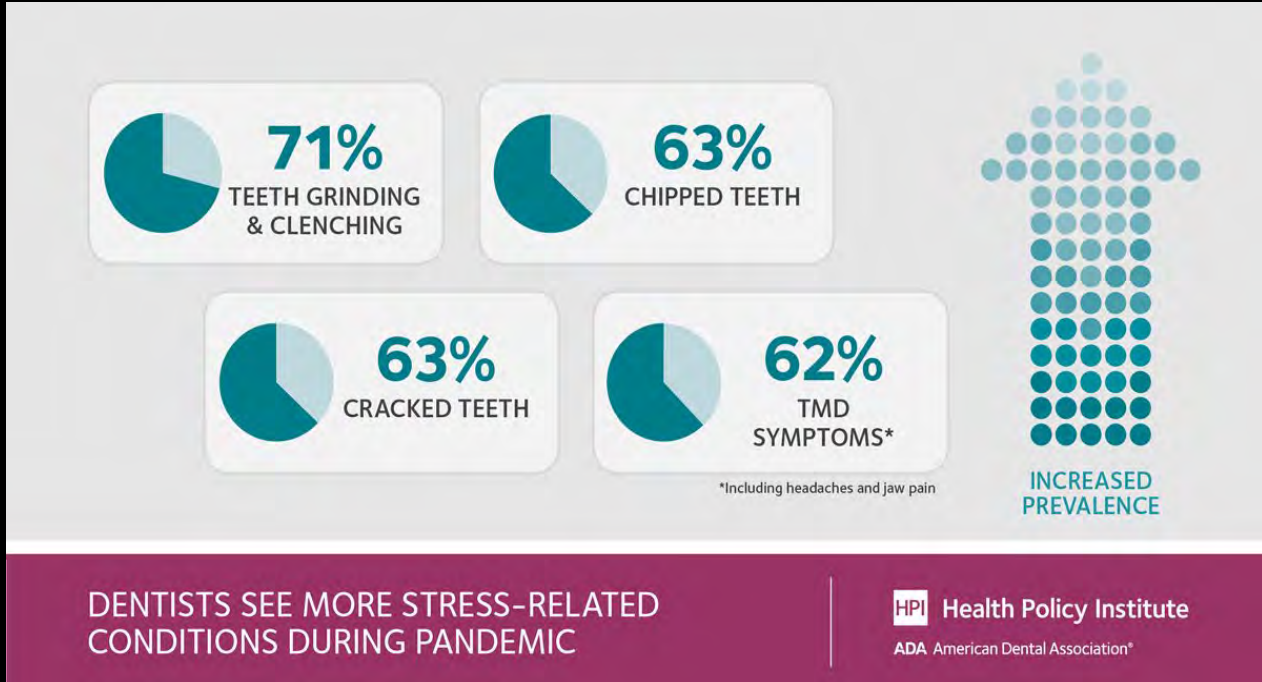
Significance

The impact of the COVID-19 pandemic on the etiologies of endodontic pathoses has not been investigated. This study showed that with the advent of the pandemic, the rates of cracked teeth increased significantly. Endodontists should be aware of indirect impacts of the COVID-19 pandemic on the etiologies of endodontic diseases.

Was the Coronavirus Disease 2019 Pandemic Associated with an Increased Rate of Cracked Teeth?

Ali Nosrat, DDS, MS, MDS,*† Peter Yu, BS,‡ Prashant Verma, DDS, MS, FAGD,*†§ Omid Dianat, DDS, MS, MDS,*† Di Wu, PhD,*†¶ and Ashraf F. Fouad, DDS, MS†*

Nosrat A, Yu P, Verma P, Dianat O, Wu D, Fouad AF. Was the Coronavirus Disease 2019 Pandemic Associated with an Increased Rate of Cracked Teeth? J Endod. 2022 Oct;48(10):1241-1247. doi: 10.1016/j.joen.2022.07.002. Epub 2022 Jul 12. PMID: 35835260; PMCID: PMC9273286.



Importance of accurate diagnosis and appropriate treatment planning is more important than ever due to the increasing rate of cracked teeth being observed

HPI poll: Dentists see increased prevalence of stress-related oral health conditions. American Dental Association. (2021, March 2). <https://adanews.ada.org/ada-news/2021/march/hpi-poll-dentists-see-increased-prevalence-of-stress-related-oral-health-conditions>

Summary



CRACKED TEETH

- Earlier detection = higher success rate for long-term preservation of tooth
- **Not all cracked teeth require RCT, but all cracked teeth require full coverage restorations (assuming tooth is restorable)**
- **RCT is only indicated if there is reproducible evidence of pulpal involvement**
- **There is no sound reason to do RCT for the sake of preserving integrity of a future crown**
- Occlusion should be evaluated at initial exam, and adjustments to reduce occlusal forces should be made if indicated
- Close recalls and monitoring should be attempted

VERTICAL ROOT FRACTURES

- Still considered “catastrophic” as a diagnosis for most teeth
- Single rooted teeth should be extracted
- Multi-rooted teeth can survive with removal of fractured root and restoration of remaining root(s), so hemisections and root amputations should still be offered as Tx options to eligible patients

Citations



Abbott, P. and Leow, N. (2009), Predictable management of cracked teeth with reversible pulpitis. Australian Dental Journal, 54: 306-315. <https://doi.org/10.1111/j.1834-7819.2009.01155.x>

Alaugaily I, Azim AA. CBCT Patterns of Bone Loss and Clinical Predictors for the Diagnosis of Cracked Teeth and Teeth with Vertical Root Fracture. J Endod. 2022 Sep;48(9):1100-1106. doi: 10.1016/j.joen.2022.06.004. Epub 2022 Jun 14. PMID: 35714728.

Basten CH, Ammons WF Jr, Persson R. Long-term evaluation of root-resected molars: a retrospective study. Int J Periodontics Restorative Dent. 1996 Jun;16(3):206-19. PMID: 9084307.

Derks H, Westheide D, Pfefferle T, Eickholz P, Dannewitz B. Retention of molars after root-resective therapy: a retrospective evaluation of up to 30 years. Clin Oral Investig. 2018 Apr;22(3):1327-1335. doi: 10.1007/s00784-017-2220-1. Epub 2017 Oct 7. PMID: 28988369.

Khasnis SA, Kidiyoor KH, Patil AB, Kenganal SB. Vertical root fractures and their management. J Conserv Dent. 2014 Mar;17(2):103-10. doi: 10.4103/0972-0707.128034. PMID: 24778502; PMCID: PMC4001262.

Krell KV, Caplan DJ. 12-month Success of Cracked Teeth Treated with Orthograde Root Canal Treatment. J Endod. 2018 Apr;44(4):543-548. doi: 10.1016/j.joen.2017.12.025. Epub 2018 Feb 21. PMID: 29429822.

Krell, K.V. and E.M. Rivera, A six year evaluation of cracked teeth diagnosed with reversible pulpitis: treatment and prognosis. J Endod, 2007. 33.

Krell KV, Cracked Teeth and Vertical Root Fractures: A New Look at a Growing Problem. American Association of Endodontists. 2022. <https://www.aae.org/specialty/wp-content/uploads/sites/2/2022/12/ecfe-2022-edition-FINAL.pdf>

Louis H. Berman, Sergio Kuttler, Fracture Necrosis: Diagnosis, Prognosis Assessment, and Treatment Recommendations, Journal of Endodontics, Volume 36, Issue 3, 2010, Pages 442-446, ISSN 0099-2399, <https://doi.org/10.1016/j.joen.2009.12.018>.

Lubisich EB, Hilton TJ, Ferracane J; Northwest Precedent. Cracked teeth: a review of the literature. J Esthet Restor Dent. 2010 Jun;22(3):158-67. doi: 10.1111/j.1708-8240.2010.00330.x. PMID: 20590967; PMCID: PMC3870147.)

Lynch CD, McConnell RJ. The cracked tooth syndrome. J Can Dent Assoc. 2002 Sep;68(8):470-5. PMID: 12323102.

Mathew S, Thangavel B, Mathew CA, Kailasam S, Kumaravadeivel K, Das A. Diagnosis of cracked tooth syndrome. J Pharm Bioallied Sci. 2012 Aug;4(Suppl 2):S242-4. doi: 10.4103/0975-7406.100219. PMID: 23066261; PMCID: PMC3467890.

Nosrat A, Yu P, Verma P, Dianat O, Wu D, Fouad AF. Was the Coronavirus Disease 2019 Pandemic Associated with an Increased Rate of Cracked Teeth? J Endod. 2022 Oct;48(10):1241-1247. doi: 10.1016/j.joen.2022.07.002. Epub 2022 Jul 12. PMID: 35835260; PMCID: PMC9273286.

Omar E. Abusteit, Sherif Hosney, Ahmed S. ElSheshtawy, Ronald Ordinola Zapata, Outcome of Endodontic Treatment through Existing Full Coverage Restorations: An Endodontic Practice Case Series, Journal of Endodontics, Volume 48, Issue 3, 2022, Pages 388-395, ISSN 0099-2399, <https://doi.org/10.1016/j.joen.2021.11.008>.

Ricucci D, Siqueira JF Jr, Loghin S, Berman LH. The cracked tooth: histopathologic and histobacteriologic aspects. J Endod. 2015 Mar;41(3):343-52. doi: 10.1016/j.joen.2014.09.021. Epub 2014 Oct 30. PMID: 25447500.


Rivera, R.M.a.W., R.E., Cracking the cracked tooth code: detection and treatment of various longitudinal tooth fractures. Colleagues for Excellence. Chicago, American Association of Endodontists, 2008

Toubes, Kênia & Quadros Tonelli, Stéphanie & Côrtes, Maria & Soares, Carlos & Bruzinga, Fábio & V Soares, Rodrigo & Silveira, Frank. (2021). The Correlation of Crack Lines and Definitive Restorations with the Survival and Success Rates of Cracked Teeth: A Long-term Retrospective Clinical Study. Journal of Endodontics. 48. 10.1016/j.joen.2021.10.010.

Vahdati SA, Torabinejad M, Handysides R, Lozada J. A Retrospective Comparison of Outcome in Patients Who Received Both Nonsurgical Root Canal Treatment and Single-tooth Implants. J Endod. 2019 Feb;45(2):99-103. doi: 10.1016/j.joen.2018.10.018. PMID: 30711185.

Endodontics. Dentist in Connellsville, PA | Chomiak Dental. (n.d.). <https://www.chomiakdental.com/endodontics>

HPI poll: Dentists see increased prevalence of stress-related oral health conditions. American Dental Association. (2021, March 2). <https://adanews.ada.org/ada-news/2021/march/hpi-poll-dentists-see-increased-prevalence-of-stress-related-oral-health-conditions>



Acknowledgements

Endodontics Faculty

- Dr. Samer M. Ebeid
- Dr. Prasanna Neelakantan
- Dr. Craig Dunlap
- Dr. Mark Stevenson
- Dr. Gordon Lai
- Dr. Michael Pham
- Dr. Alan Gluskin
- Dr. Adham A. Azim
- Dr. Sarah Nash
- Dr. Keith V. Krell
- Dr. Domenico Ricucci

Restorative Faculty

- Dr. Karen Schulze
- Dr. Foroud Hakim
- Dr. Florence Ngo
- Dr. Desmond Ng
- Dr. Sandra McLaren

Laboratory Faculty

- Carlos Correa
- Alfredo Riley
- California Dental Arts (CDA)

Administrative Faculty

- Lucy Wright-Nielsen
- Marceyl Jones

Thank you for the education, guidance, and experiences you have all provided for me.

This case solidified for me the importance of proper diagnostic testing, and to really dig for the “why” behind a patient’s chief complaint. The importance of documentation and informed consent also became more apparent during this process. By properly informing the patient of the potential of needing root canal treatment down the line, even after delivery of the final restorations, the dentist has covered their bases and is no longer on the hook should the patient get upset in the case of such an event. Thankfully, my patient is now asymptomatic, still has her vital teeth, and is fully aware that root canal treatments may be required down the line.

OKU Sutro Excellence Day Project Cover Sheet

Project Title

Full name(s) and class year(s) of all project collaborators

Example: Jane Smith, DDS 2022; John Smith, DDS 2022

Project Category

Enter your abstract text here (max 300 words)