

# Endosseous Implant Placement in the Le Fort I Maxilla

---

Kathleen Phan, DMD  
AEGD 2024

UNIVERSITY OF THE  
**PACIFIC**  
Arthur A. Dugoni  
School of Dentistry



# Intro

My name is Kathleen Phan

Graduated from Tufts School of Dental  
Medicine in 2023.

PGY-1 2024 AEGD UOP

Born and raised in the San Jose. Will  
be practicing in the Peninsula and  
South Bay Area



**CC: “I want to fix  
my smile”**

HPI: Pt presents for POE. Pt reports that he had extensive dental work completed since his childhood in Poland.

# Patient History

Social Hx: Patient is a retired electrical engineer. Pt lives in the East Bay Area with his wife. Has adult children. No hx of smoking, drinks socially.

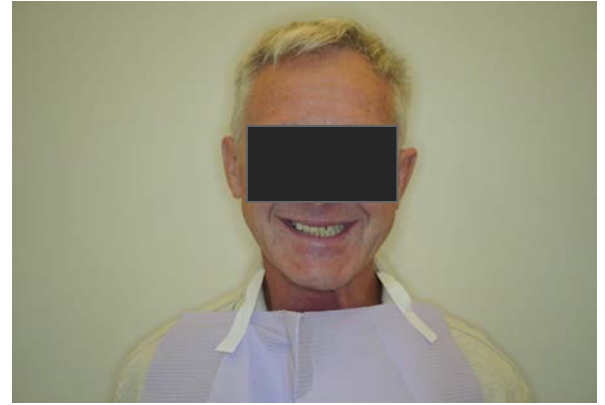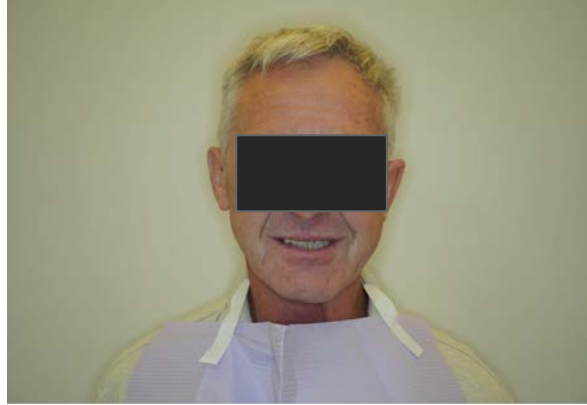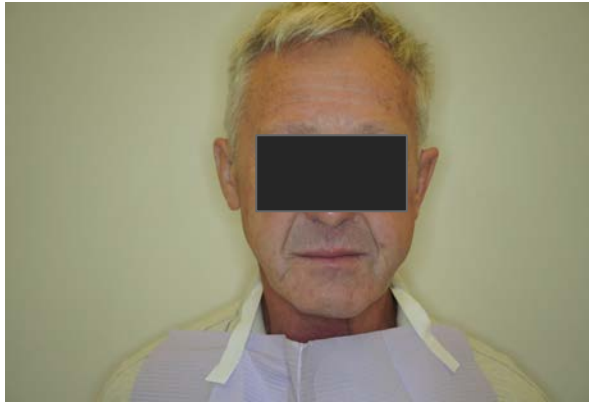Medical hx: HTN

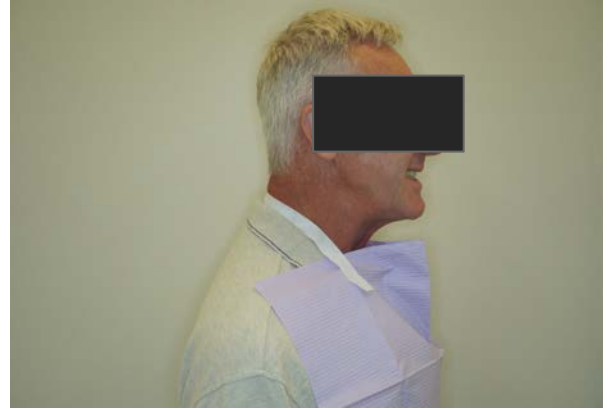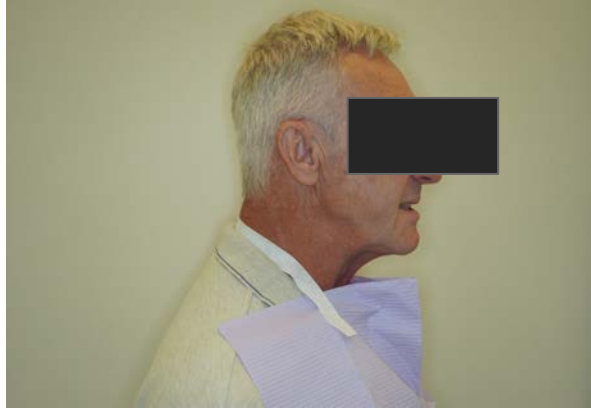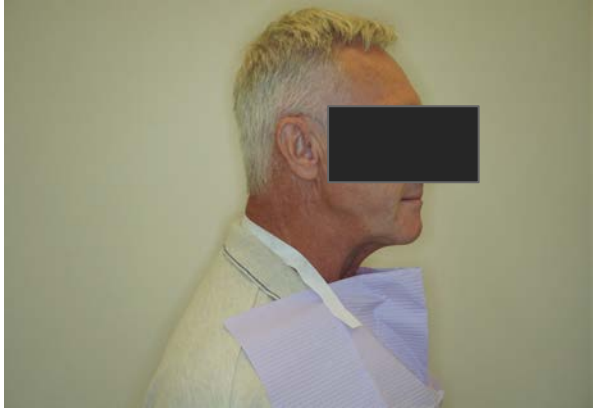Allergies: NKDA

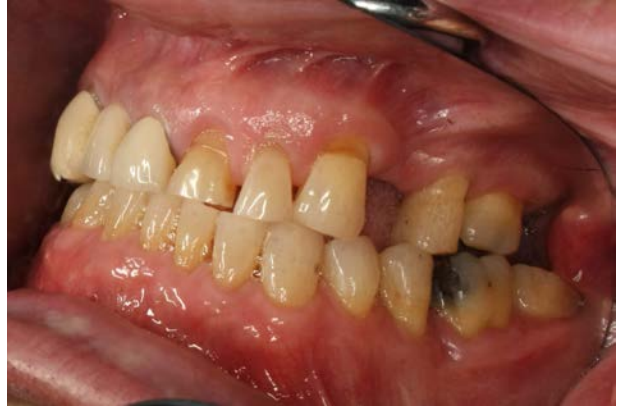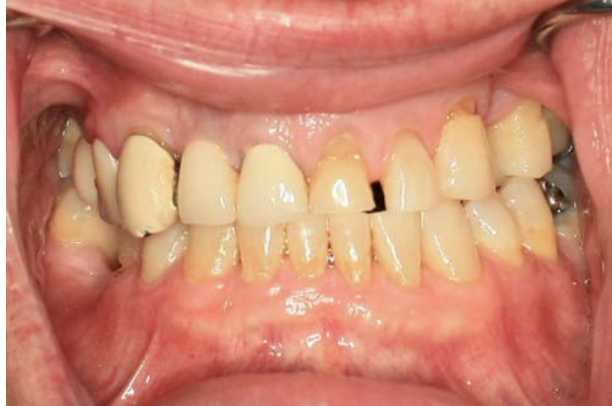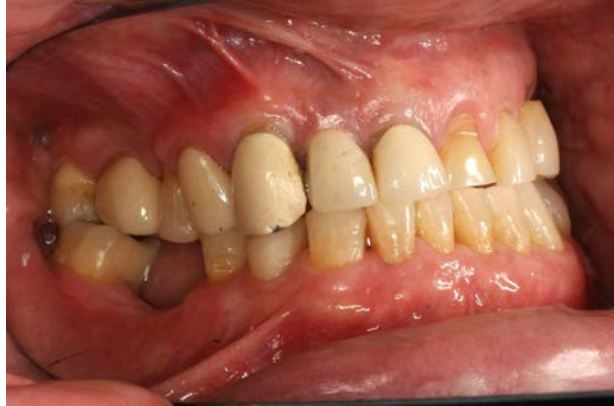Medications:

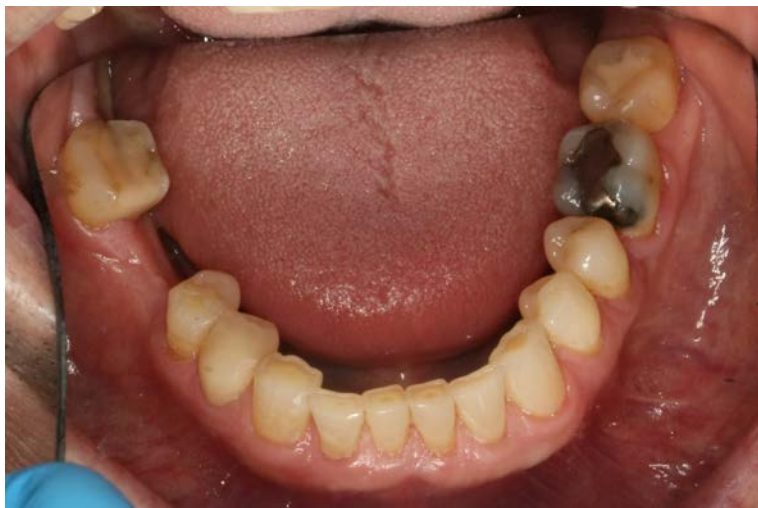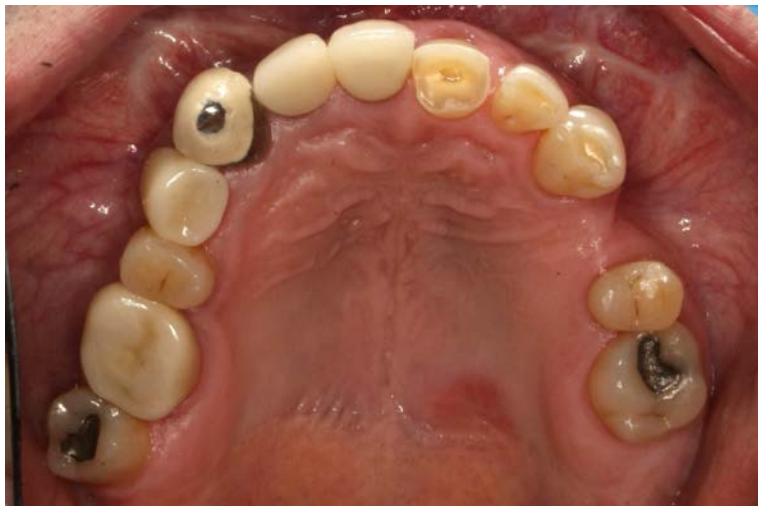Lisinopril 10mg - QD

Propranolol 5mg - QD





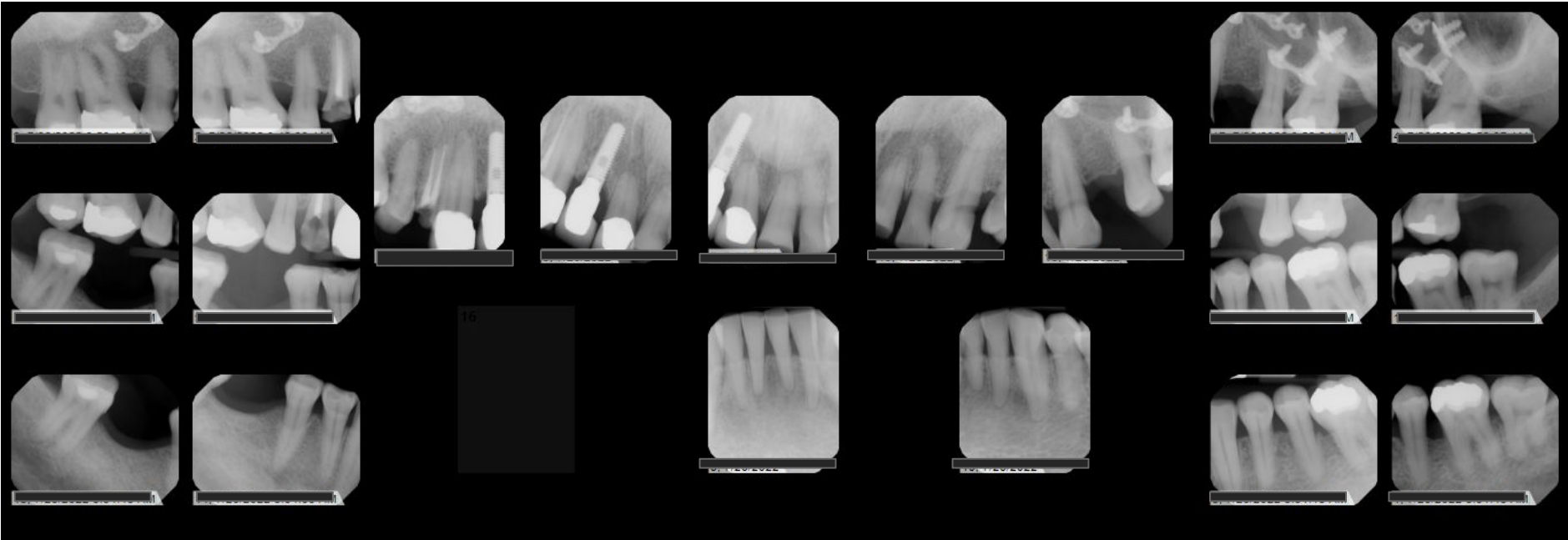




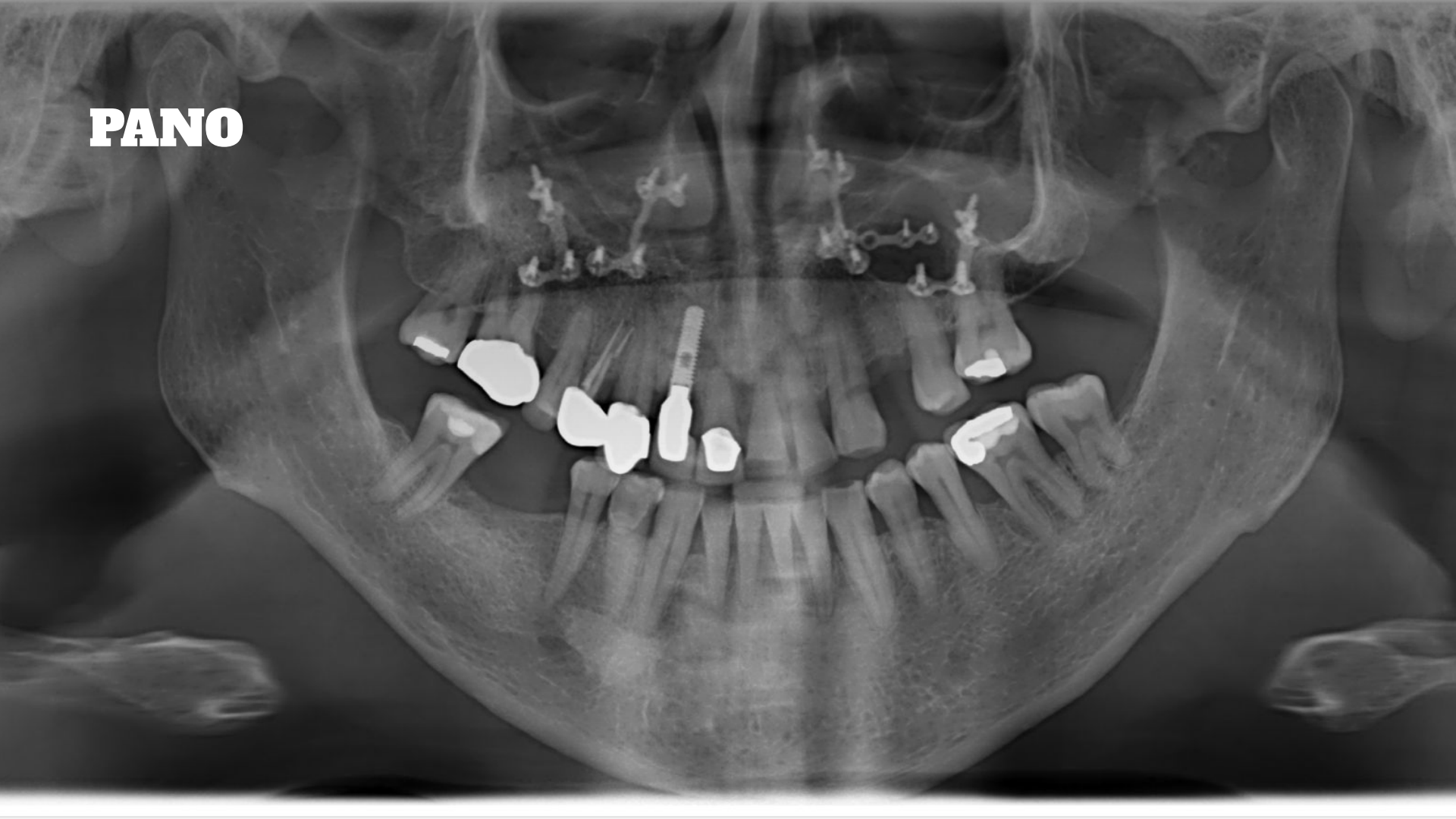## DENTAL HISTORY:

- Orthodontia ~1961 in Poland
- Le Fort I osteotomy ~15 years ago + Ortho
- Orthodontia 2022 w/ Dr. Ricupito for extrusion of #5 for restorative purposes
- Occlusion: R – Canine Class III, L – Canine Class I
- Notable generalized attrition observed
- #2 and #5 crowns delivered in spring 2023
- Pt expressed dissatisfaction w/ bulbous appearance of #6 PFM crown
- #6 has open margins
- Perio: Generalized Chronic Moderate Periodontitis Grade B Stage II – PD <5mm
- CAMBRA:
  - Caries Risk High
  - ATP Score: 2851 (from last POE 3/2023)
  - pH 6





**PANO**



# Dental Findings

#1 O(a)

#2 PFM

#3 missing

#4 RCT, PFM abut

#5 CZ crown

#6 PFM crown

#7 Implant, PFM cement crown

#8 PFM crown

#9 Attrition

#10 Attrition

#13 Attrition

#14 missing

#15 O(a)

#17 O(c)

#18 MO(a)

#20-27 Attrition

#28 OB(c)

#29 B Abfraction

#30 missing

#31 missing

#32 MO(c)

# TX OPTIONS

## TX OPTION 1

- Phase 1: Diagnostic/Prophylactic  
Resident Review  
SPT  
CAMBRA
- Phase 2: Operative  
#17 O GI
- Phase 3 Major Restorative  
#6 PFM Replacement  
#12 CZ Crown  
#30 CZ Crown
- Unphased Endo/Surgical  
#12 Implant Placement  
#30 Implant Placement

## TX OPTION 2

- Phase 1 Diagnostic/Prophylactic  
Resident Review  
SPT  
CAMBRA
- Phase 2 Operative  
#17 O GI
- Phase 3 Major Restorative  
#6 PFM Replacement  
#11-x-13 FPD  
#29-x-31 FPD

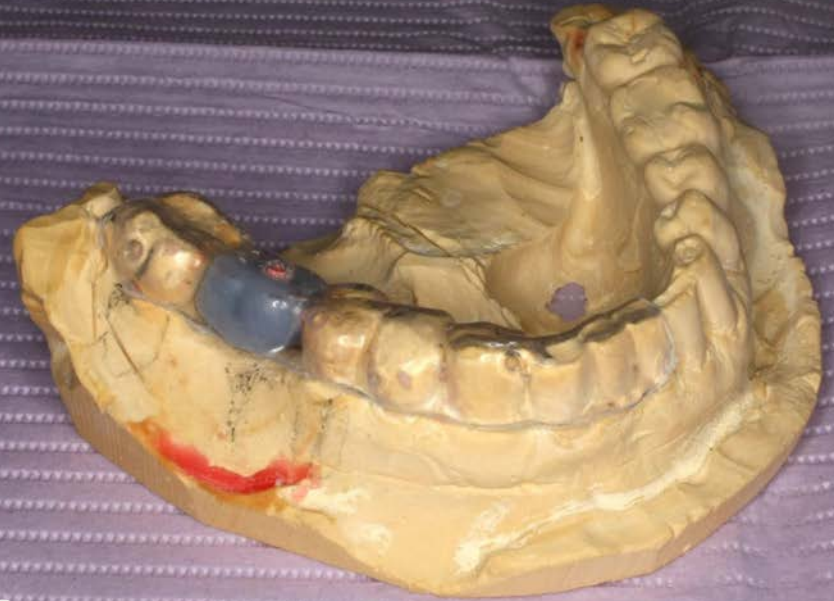
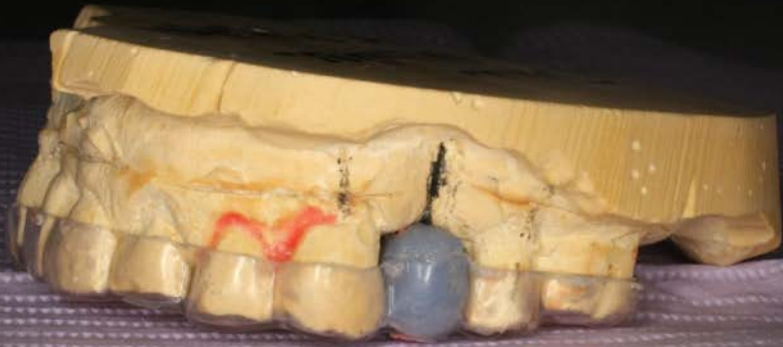# TX OPTIONS

## TX OPTION 1

- Phase 1: Diagnostic/Prophylactic  
Resident Review  
SPT  
CAMBRA
- Phase 2: Operative  
#17 O GI
- Phase 3 Major Restorative  
#6 PFM Replacement  
#12 CZ Crown  
#30 CZ Crown
- Unphased Endo/Surgical  
#12 Implant Placement  
#30 Implant Placement

## TX OPTION 2

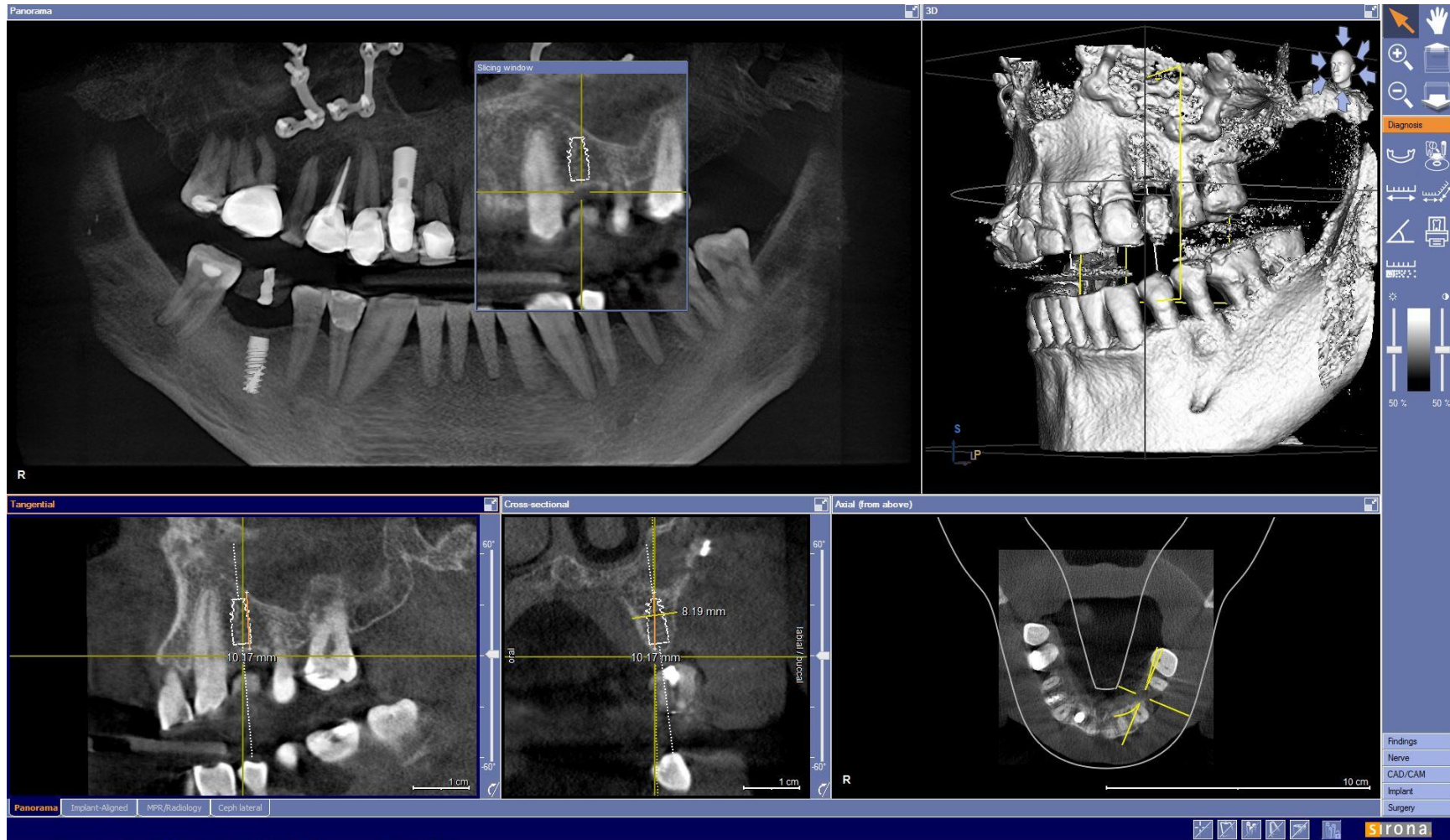
- Phase 1 Diagnostic/Prophylactic  
Resident Review  
SPT  
CAMBRA
- Phase 2 Operative  
#17 O GI
- Phase 3 Major Restorative  
#6 PFM Replacement  
#11-x-13 FPD  
#29-x-31 FPD



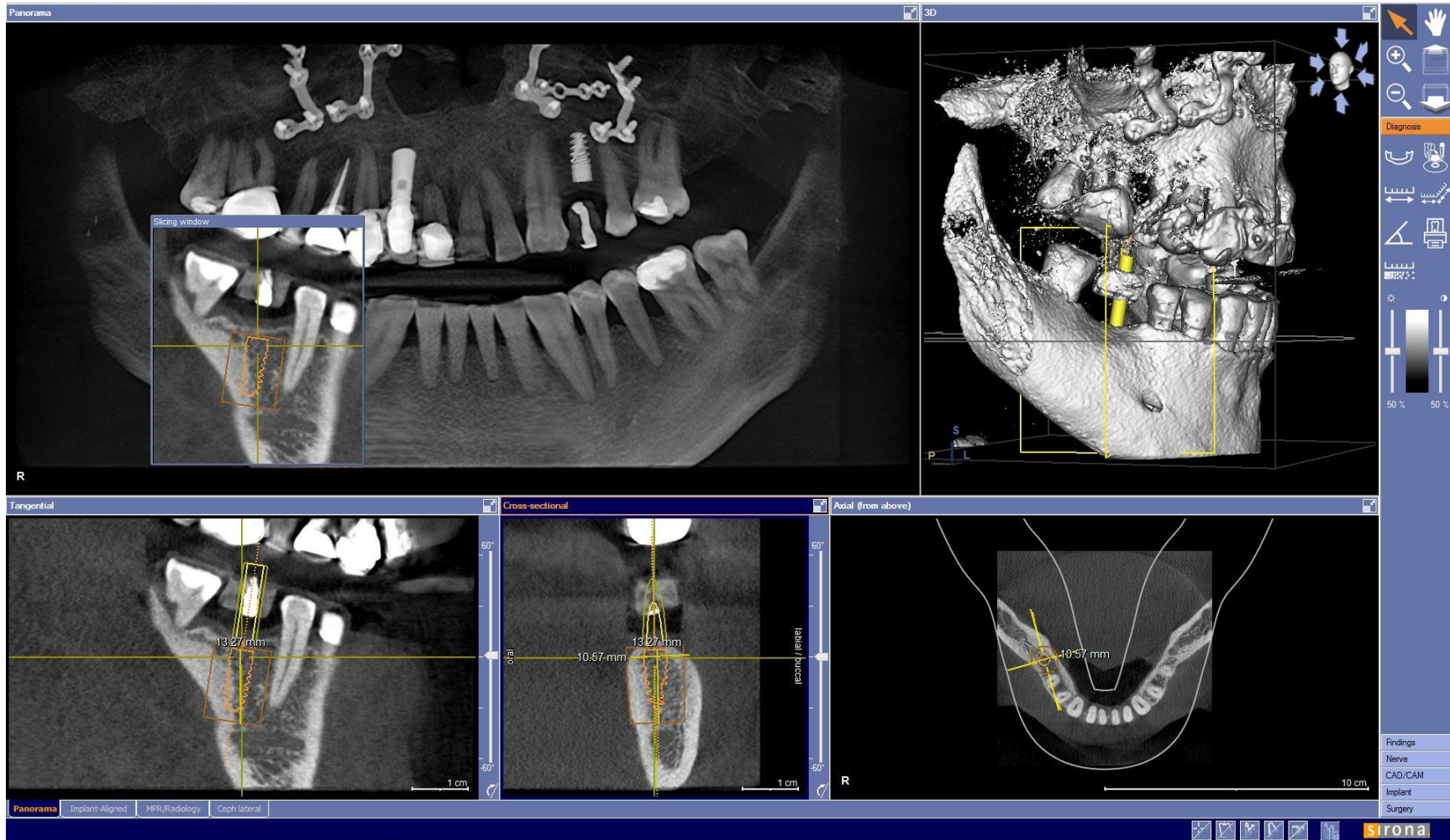
# **RADIOGRAPHIC STENTS**



#12



#30






# IMPLANT SELECTION

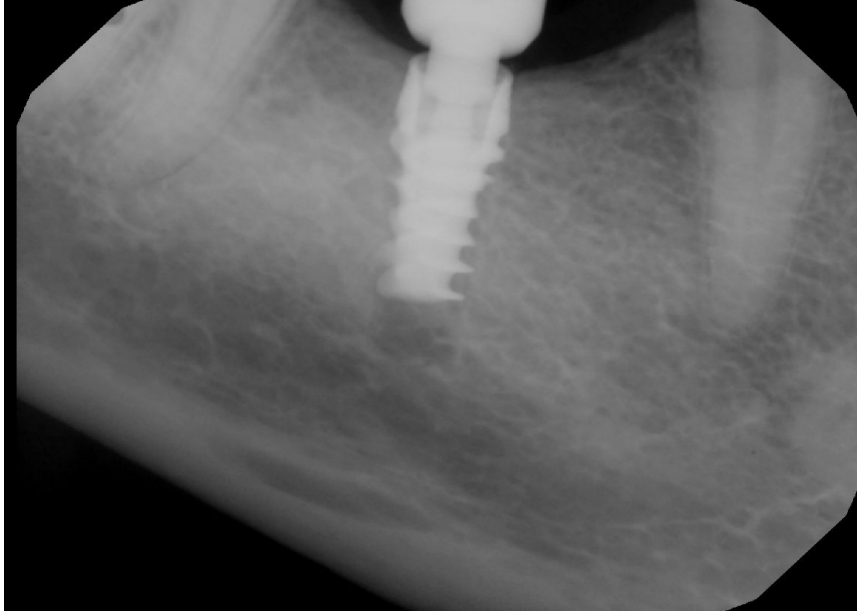
- Nobel Active  
Internal Conical  
Connection  
Textured Collar
- #30  
NobelActive RP 4.3 x  
10mm
- #20  
NobelActive RP 4.3 x  
8.5mm

NP 3.5  
RP 4.3  
RP 5.0

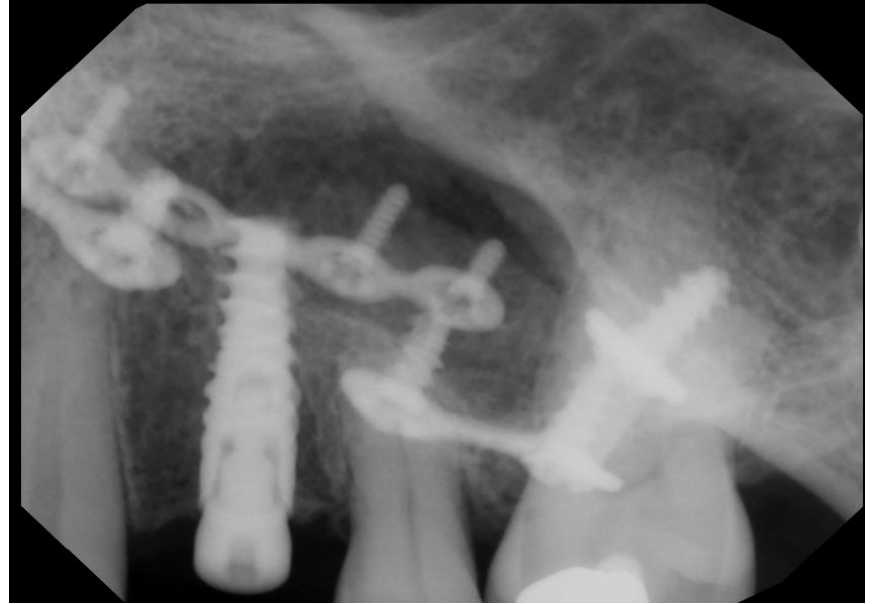


# Post Op Plans

- 1) 1 week FU to assess healing and osseointegration**
- 2) 2 phase implant placement  
3-4 months healing before crown placements**
- 3) During waiting period fabrication of #6 crown**

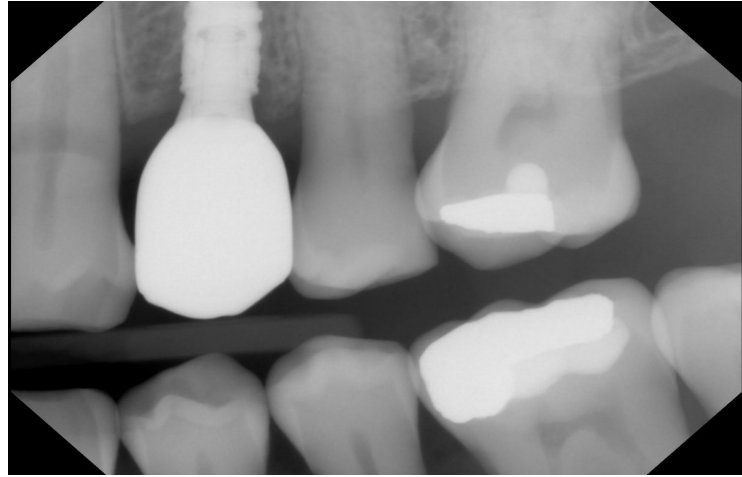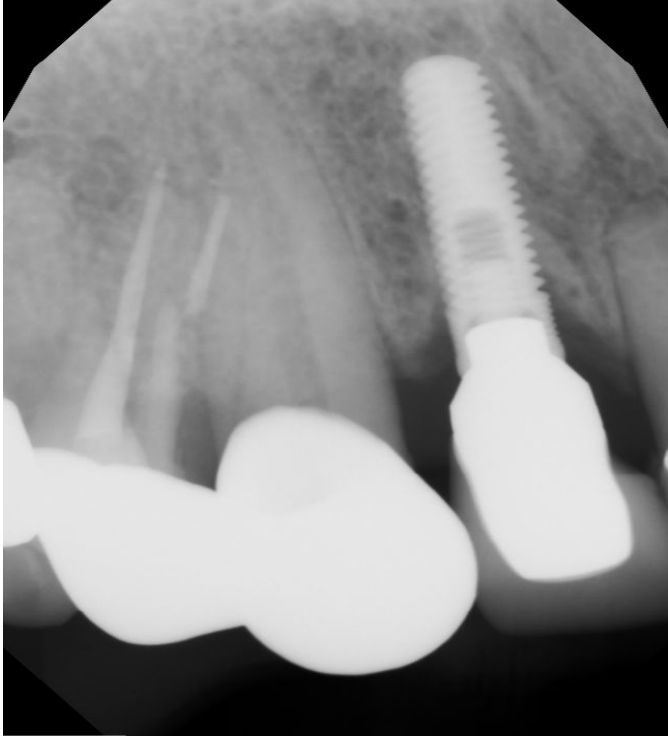


**#30**

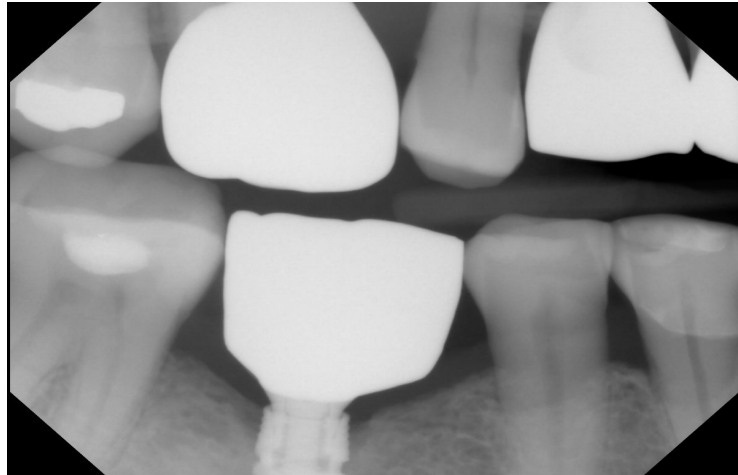


**#12**

**#6  
layered  
zirconia  
crown**



**#12**



**#30**

**Pt was  
informed to  
keep these  
area clean  
due to  
generalized  
perio**

# **Questions?**

**Special thank you to the Union City Team, Dr. Allen Wong, Dr. Debra Woo, Dr. William Lee, and Dr. Michael Beckley**