

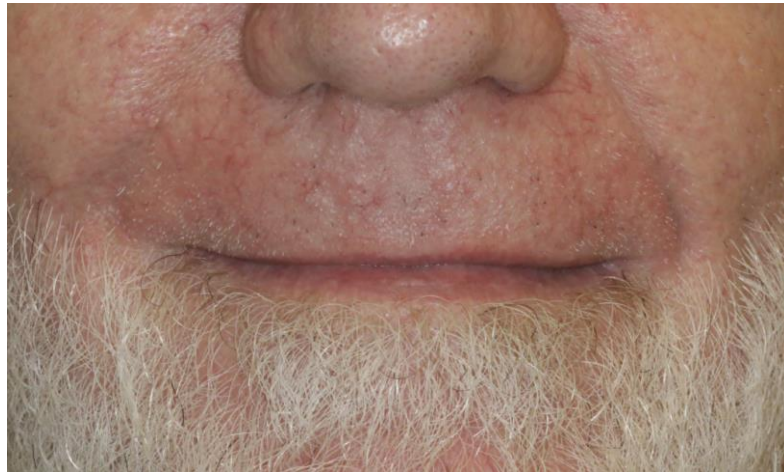Opening VDO with a Combination of Fixed and Removable Prosthesis in a Bruxer

Greg Polonsky DDS 2021

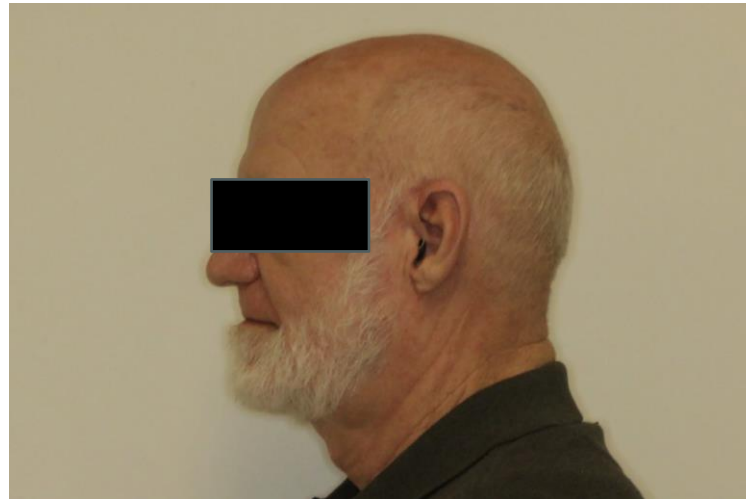University of the Pacific, Arthur A. Dugoni School of Dentistry



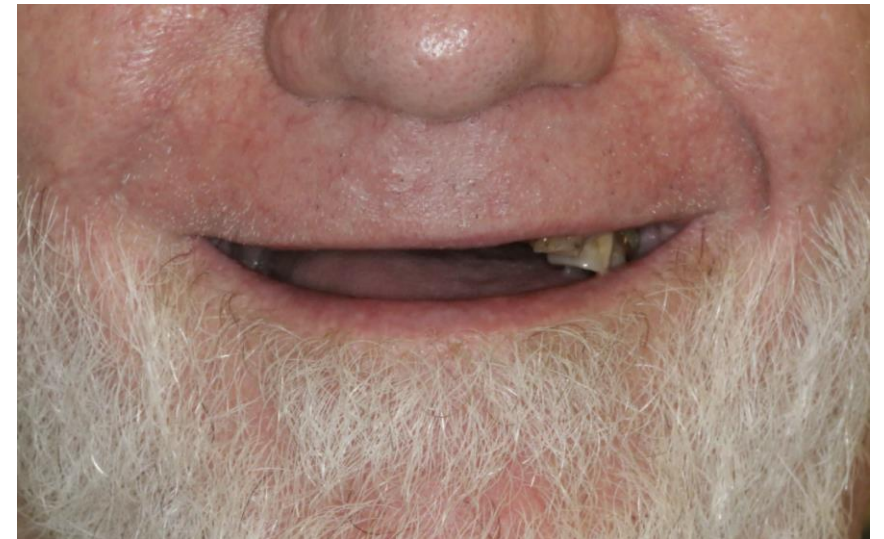Extraoral Photos



Repose

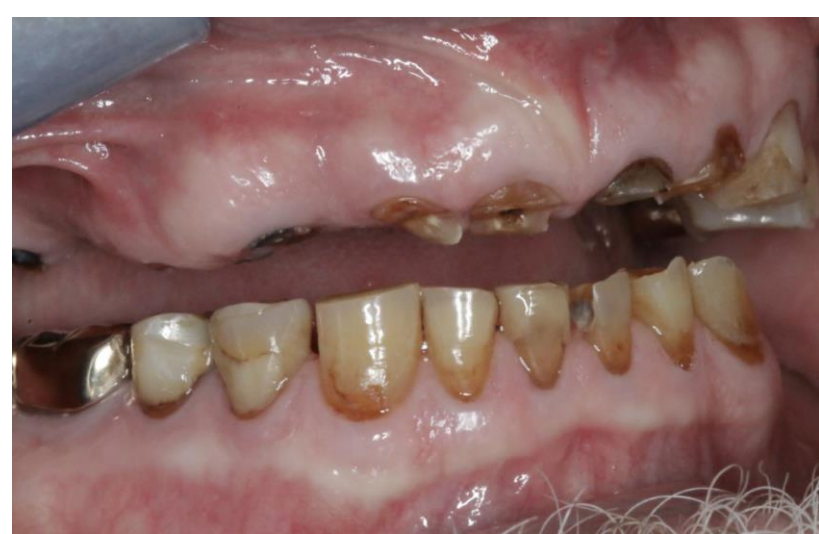

Sagittal Profile

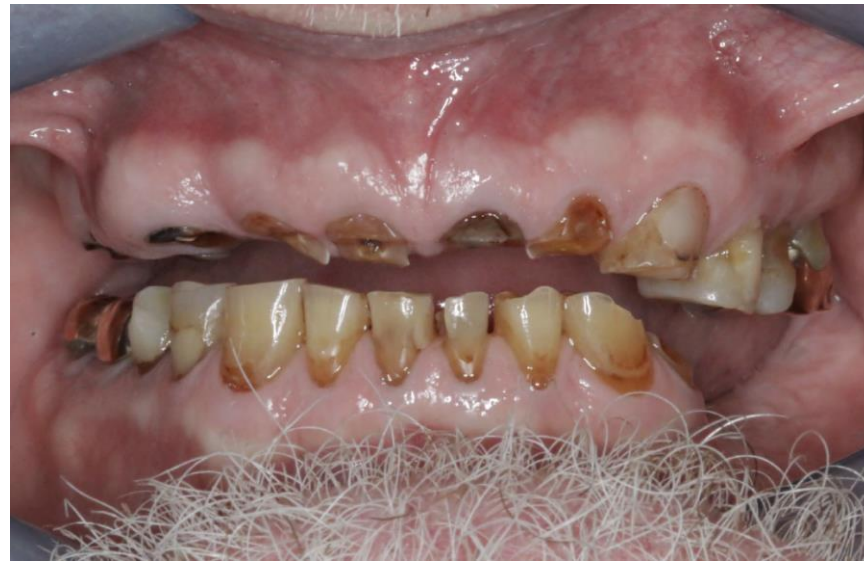

Smiling

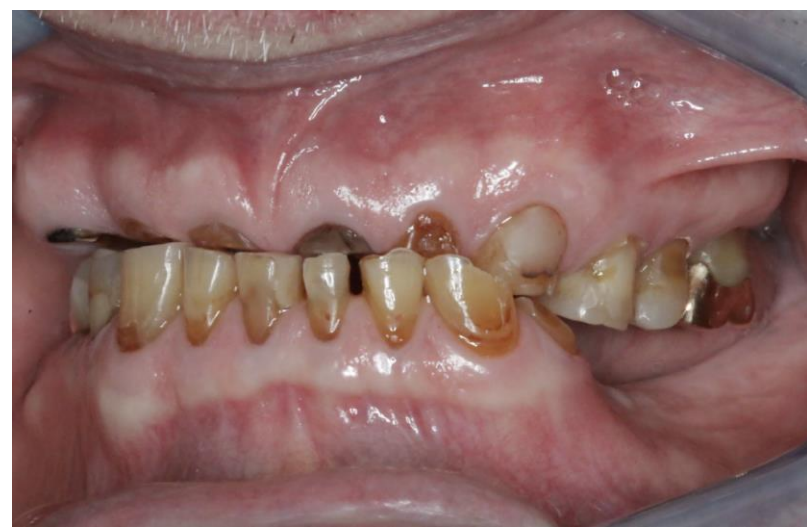Intraoral Photos



Right

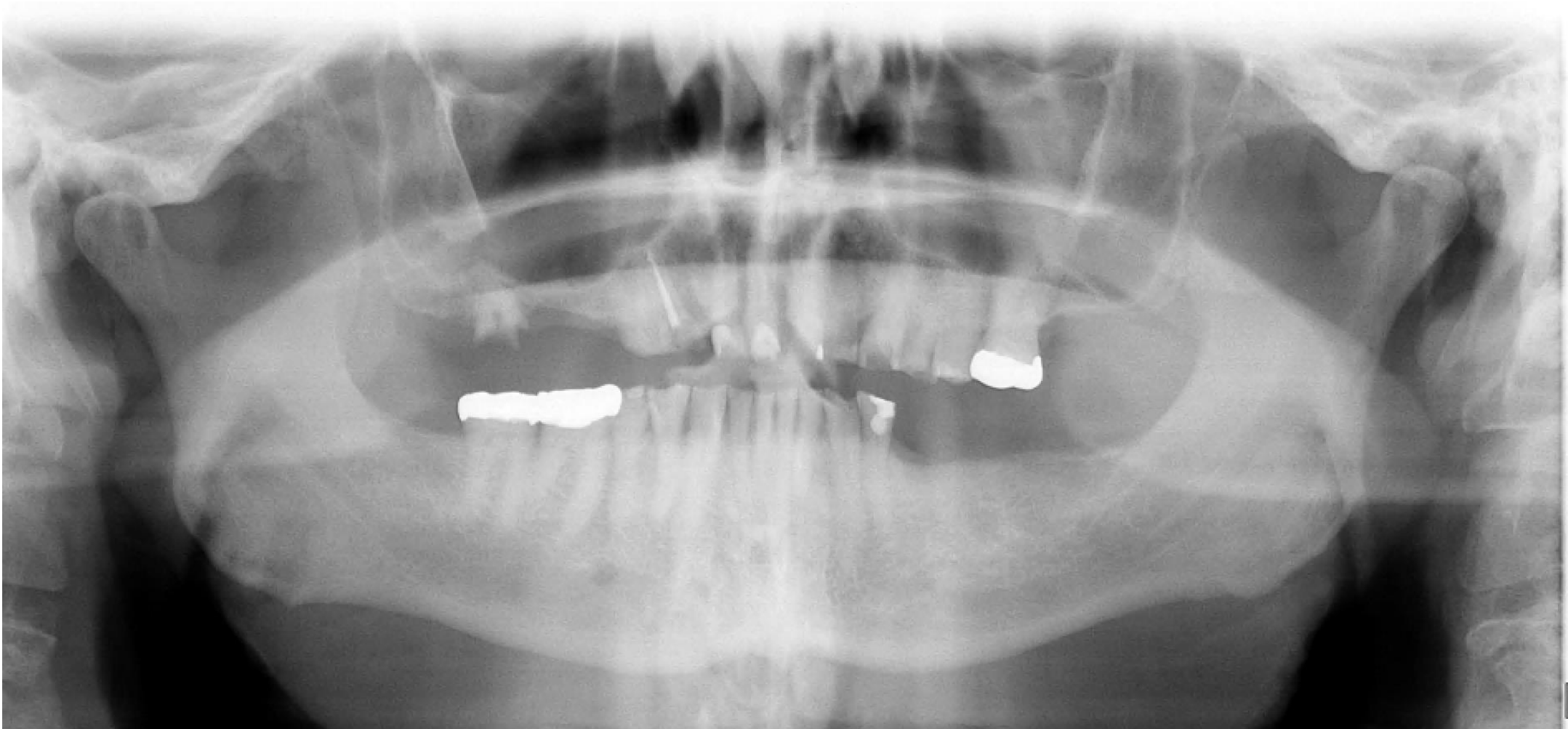


Front



Left

Panoramic – 3/28/2018



Ideal Tx Plan Overview

- Urgent
 - No urgent care indicated
- Disease
 1. Prophy
 2. Extraction of #2, 5, 6, 7, 8, 9, 10, 11, 12, 13, 14, 21
- Restorative
 1. Direct restorations #24 & 25
 2. Crown #22
 3. UA Complete Denture
 4. Implants #19 – 21
- Maintenance
 - Proper OHI once tx completed
 - Mx overdenture if pt desires

Preoperative Sx Guide



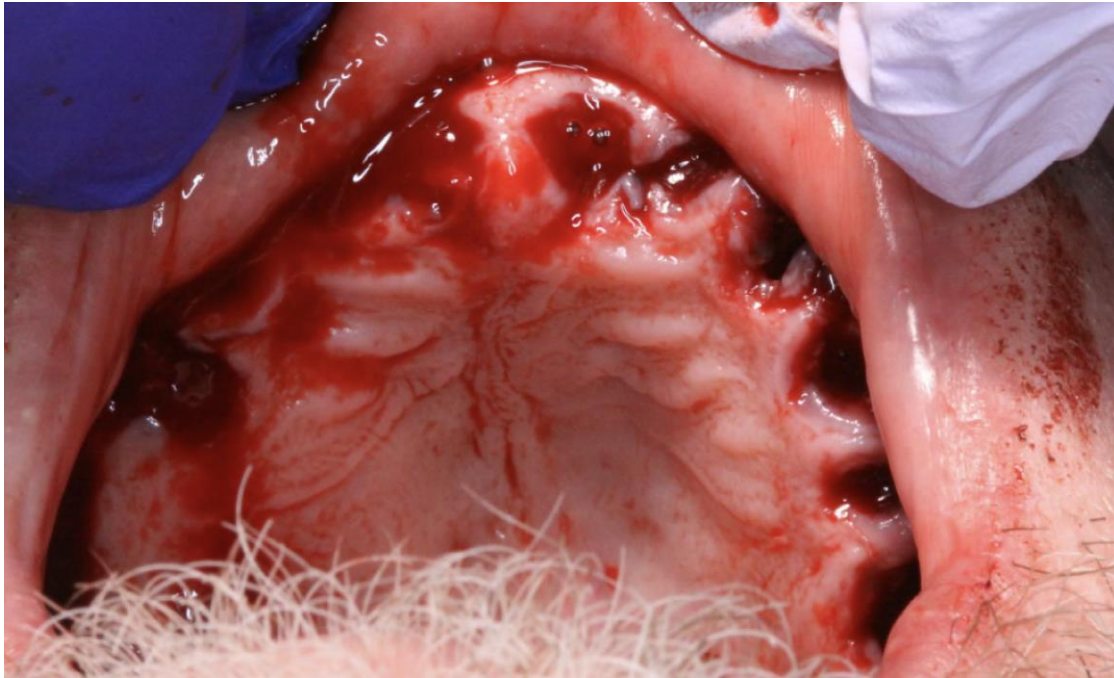
Surgical Guide



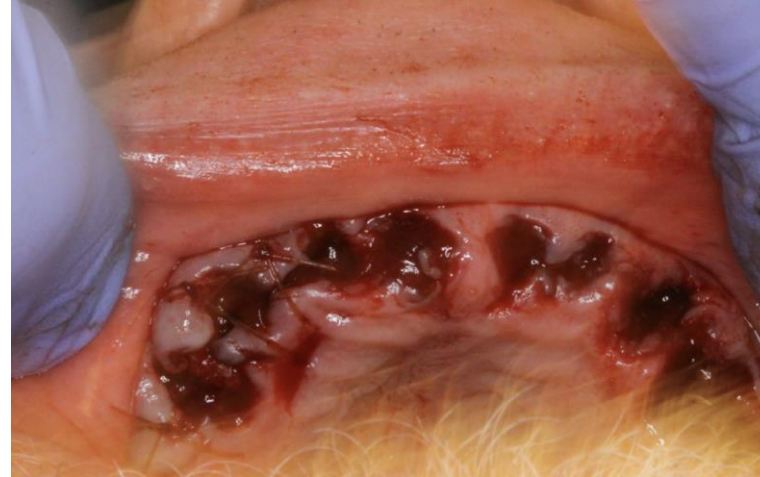Clockwise:

- Altered master cast made with help from Dr. Hoover
- Denture alginate cast for custom tray
- Surgical guide
- Duplicate altered master cast for suckdown splint

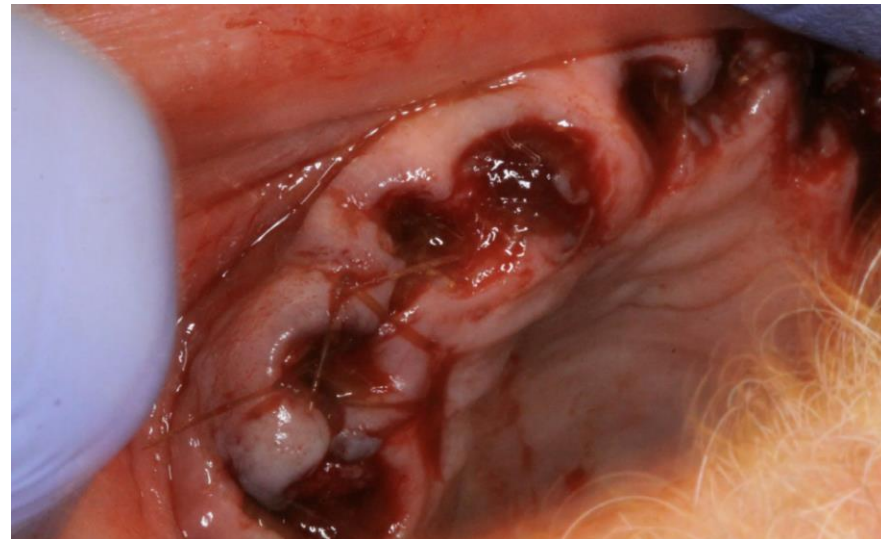
Postoperative – 11/16/2020



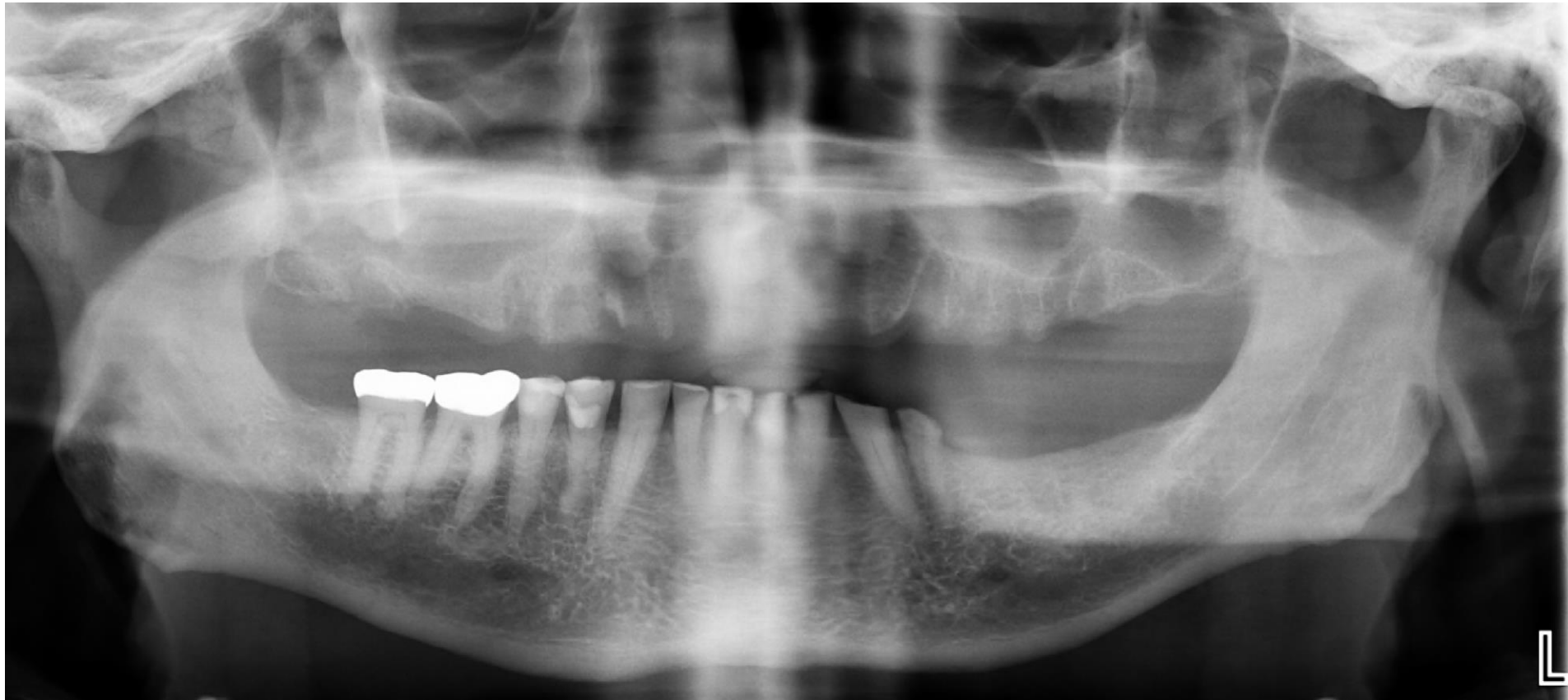Axial View



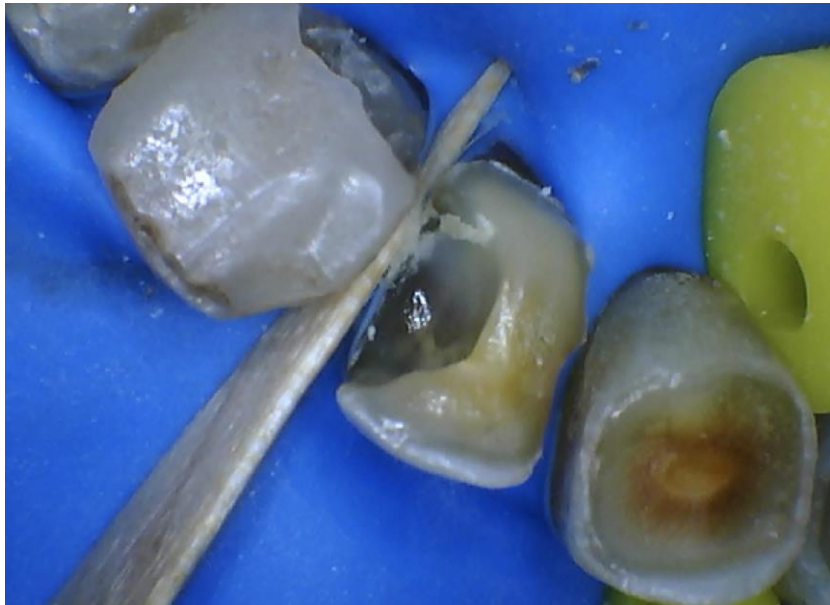
4-0 Chromic Gut
placed in UR



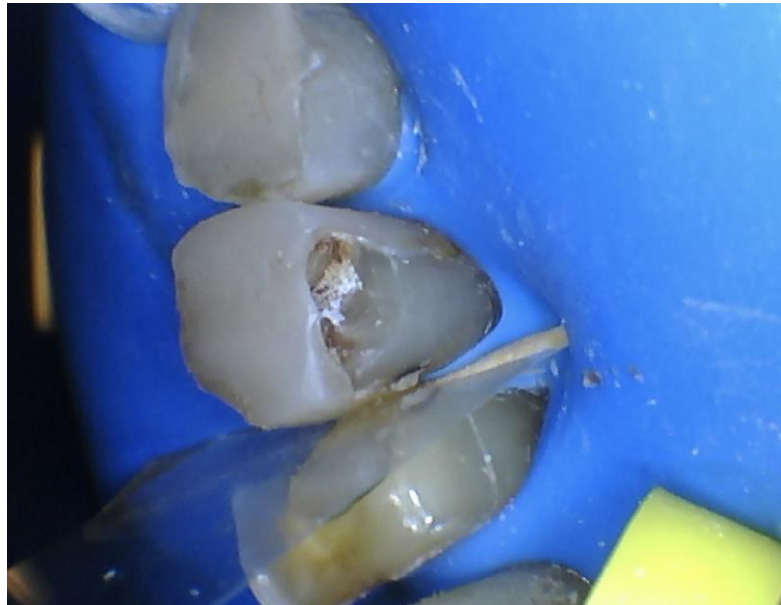Post-Op Pano – 12/9/2020



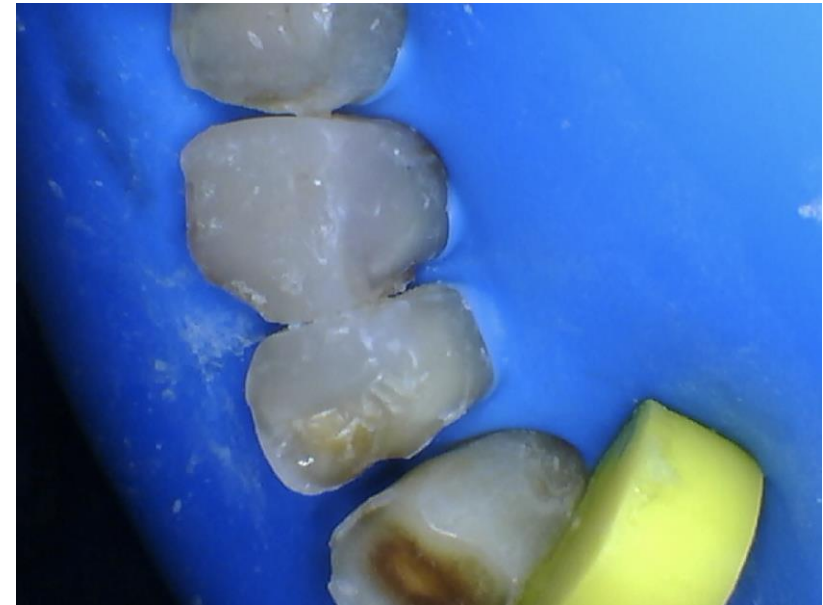Direct Restorations – 1/13/2021



#24 Caries Excavated



#25 Caries Excavated



Final Fill

UA Records – 1/29/2021



VDR variable and closest speaking space used to estimate VDO as per Dr. Curtis

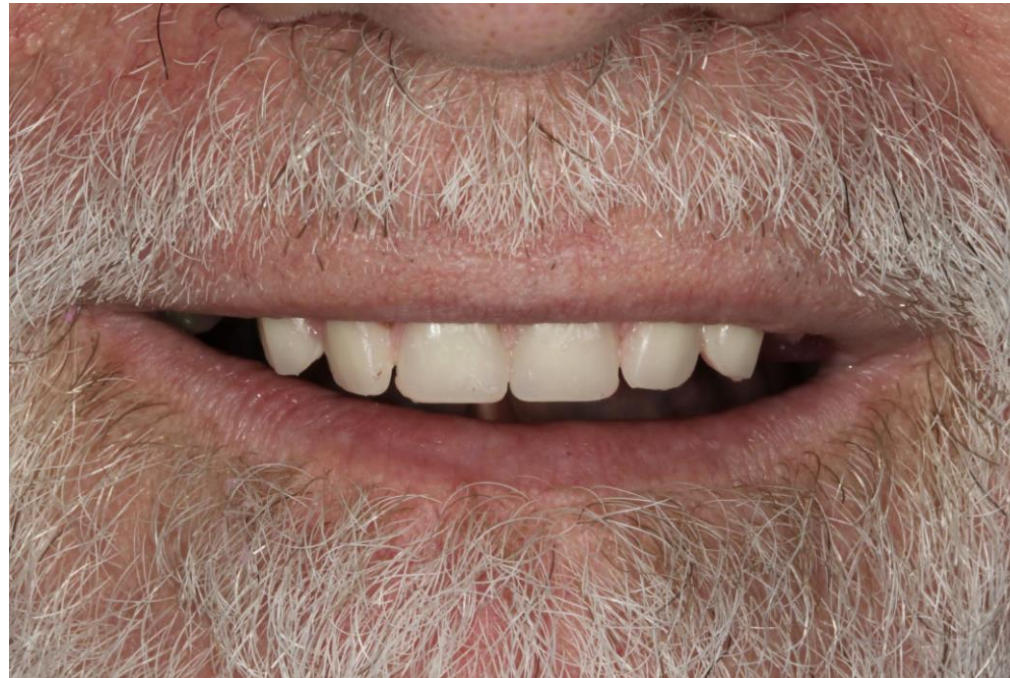


Anterior 6 set-up begun, need to be shifted apically and distally



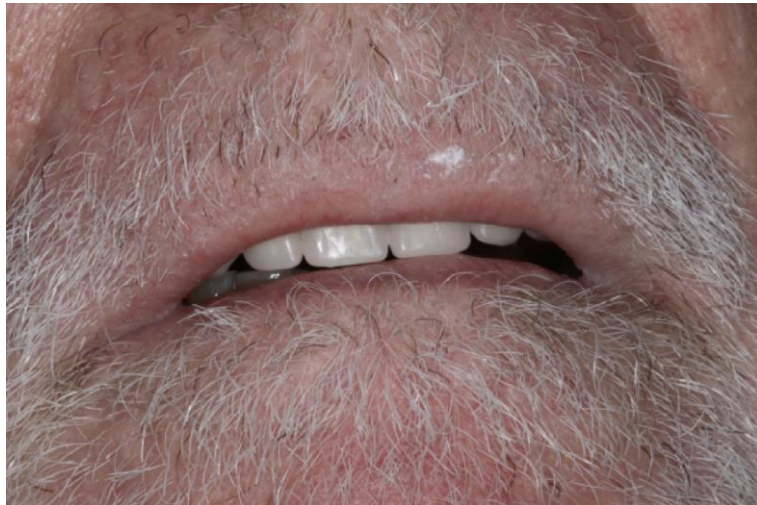Anterior 6 set-up left view

Anterior 6 Try-In – 2/11/2021




Smiling – teeth aligned with facial midline and interpupillary line but not with lower lip

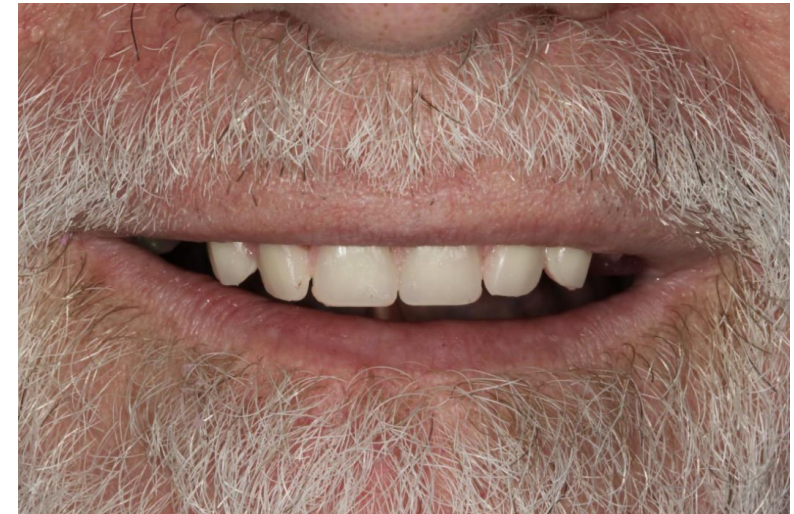
New Ant. 6 Set-Up – 2/24/2021



Repose

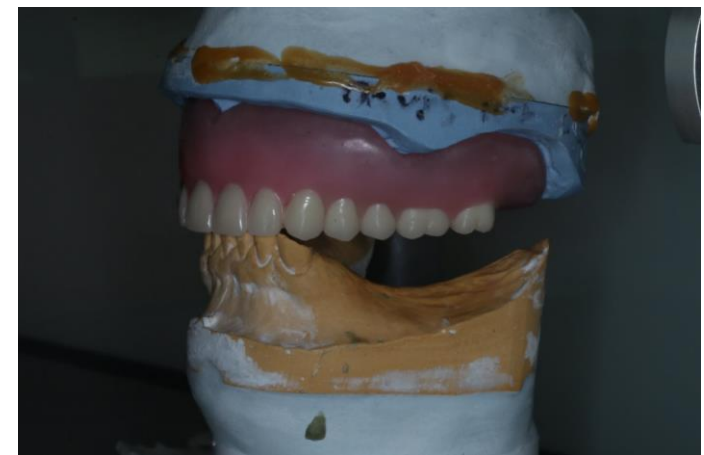
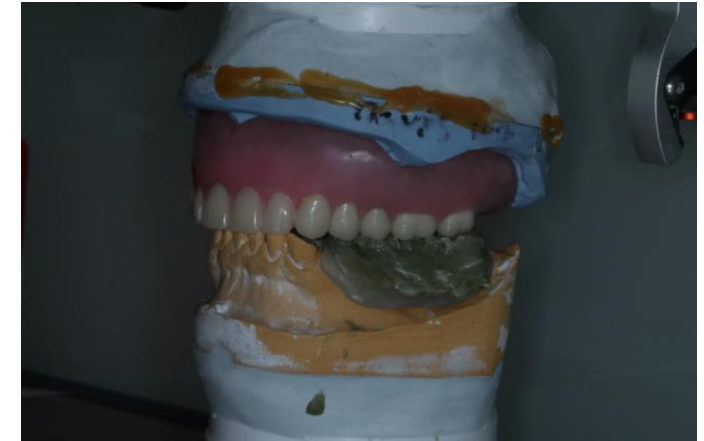
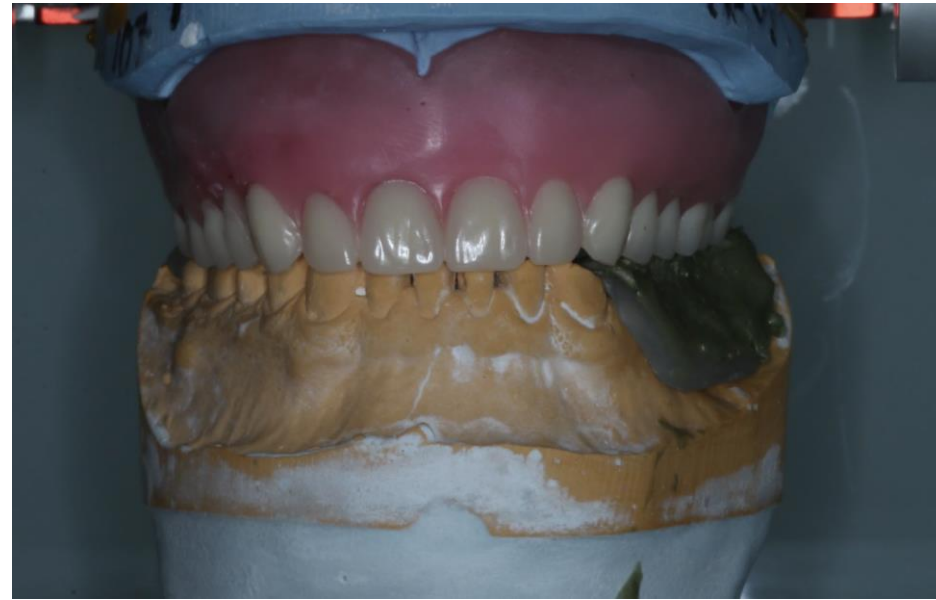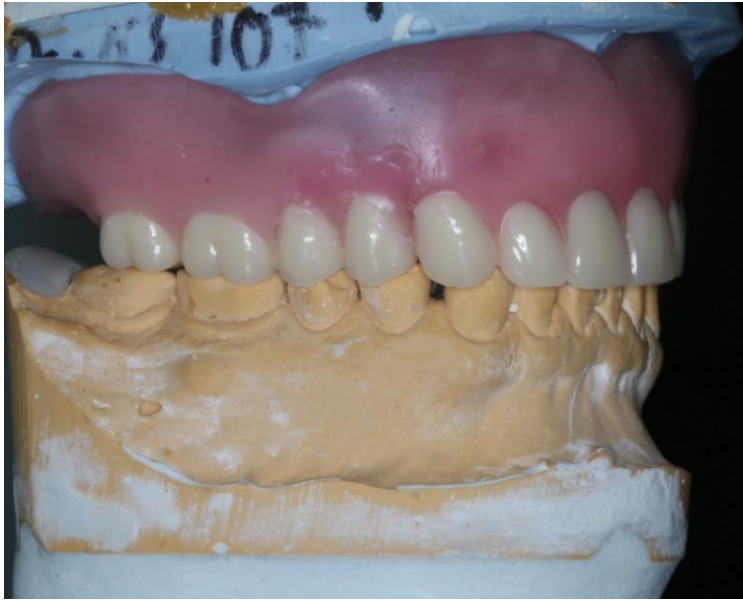Facial Profile

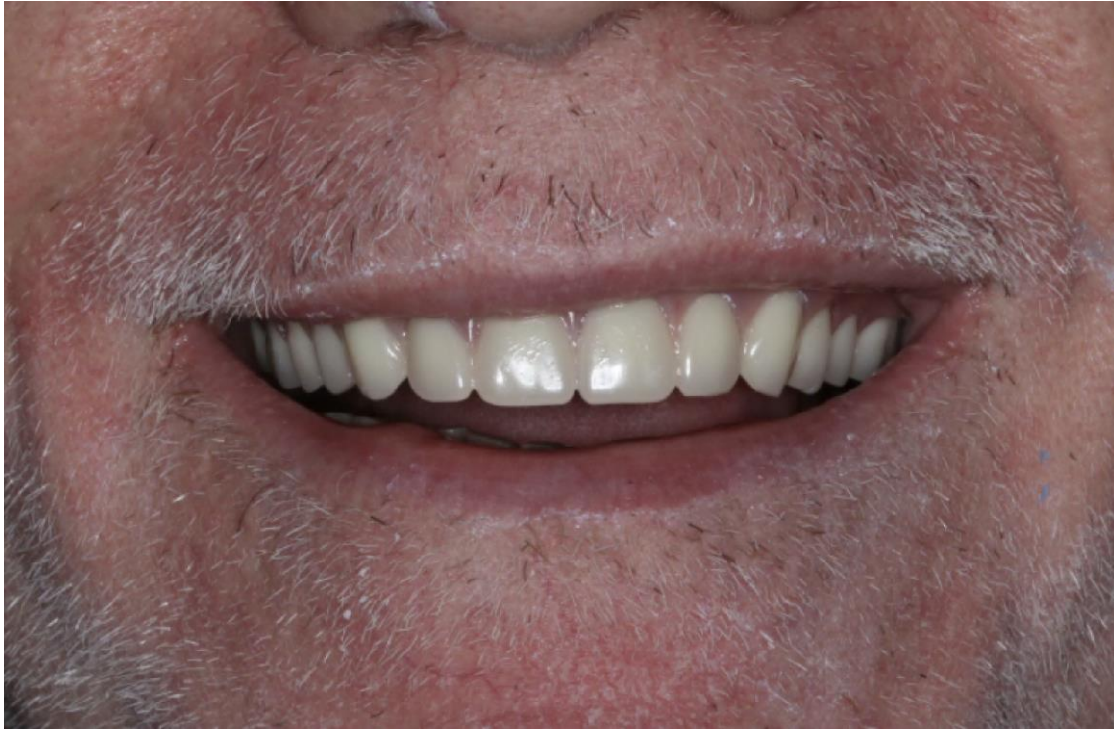

Smiling

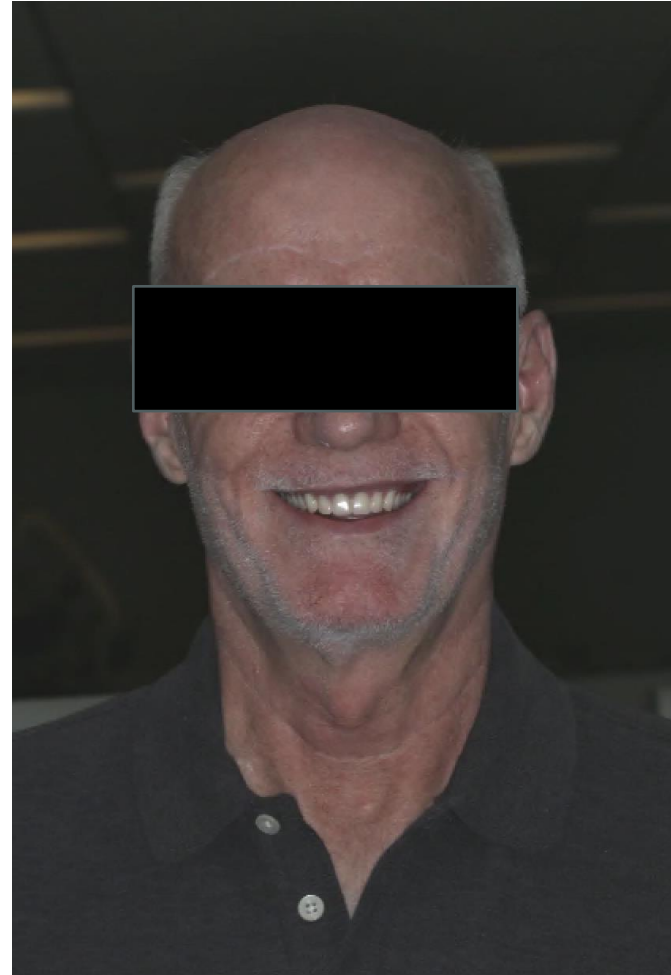
Posterior Try-In – 3/31/2021



Delivery – 4/21/2021

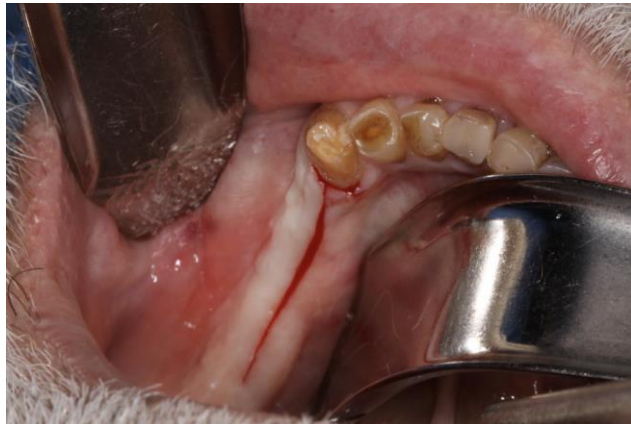

Smiling

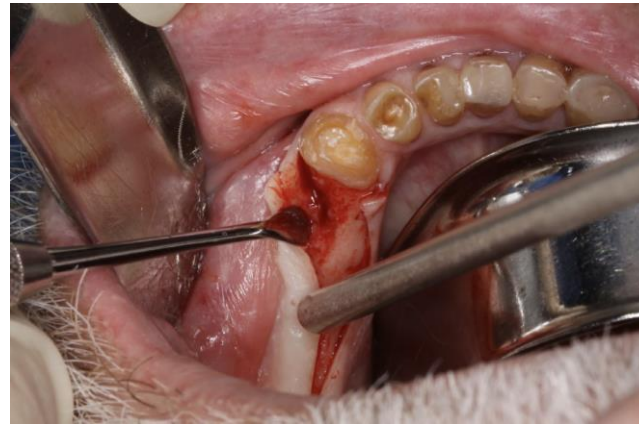


Facial Profile

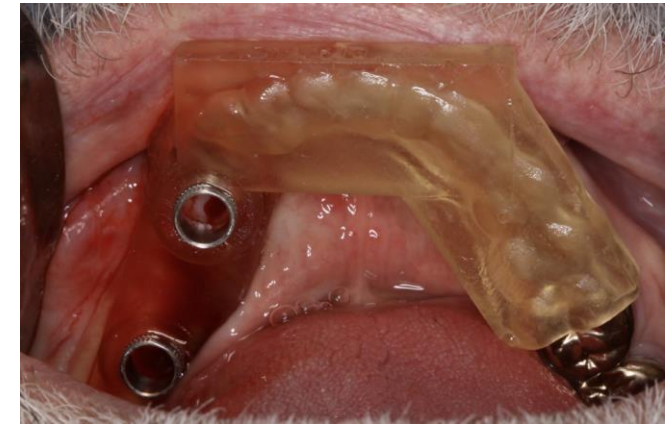Implant Surgery – 4/7/2021



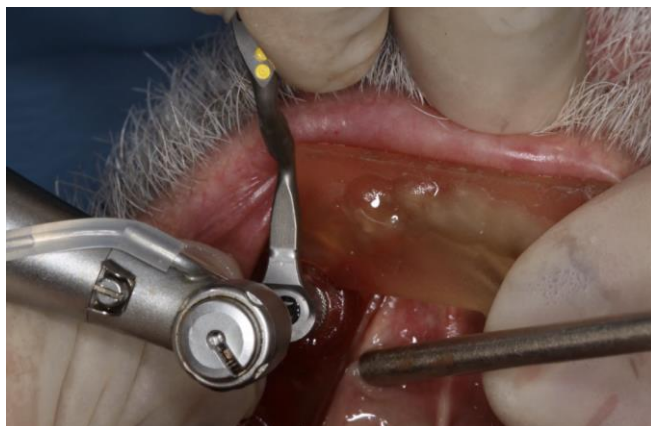Paramedial incision made



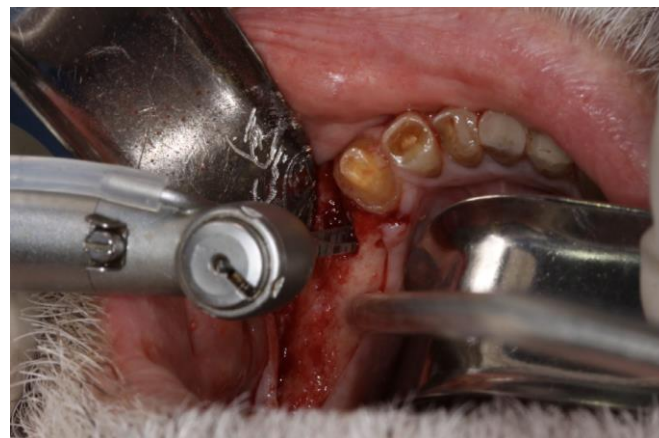FTMP flap raised



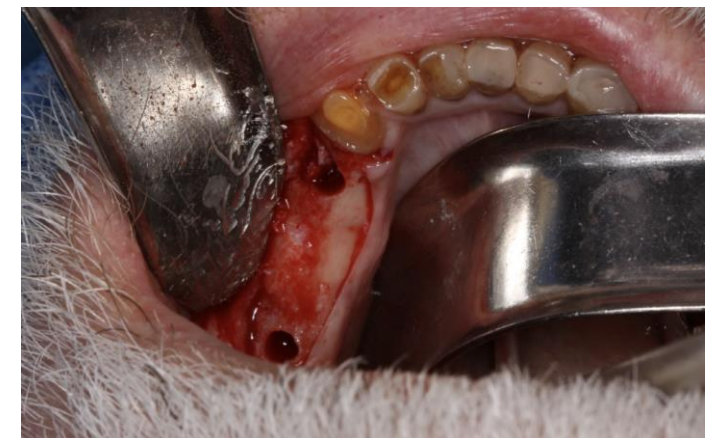Sx guide fitted



Implant trajectory established

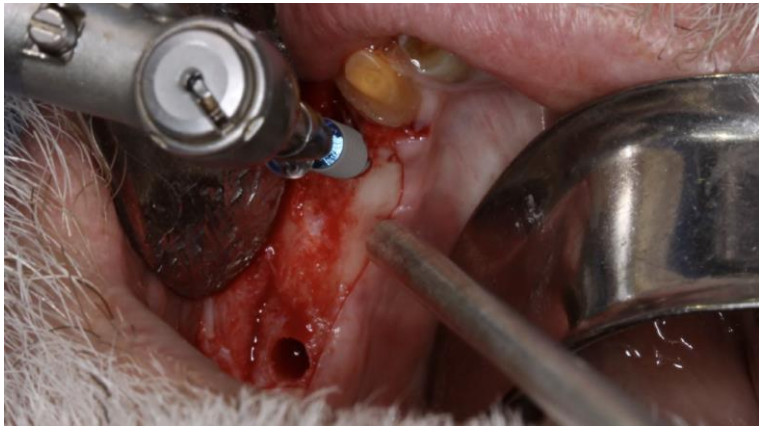

Osteotomy created

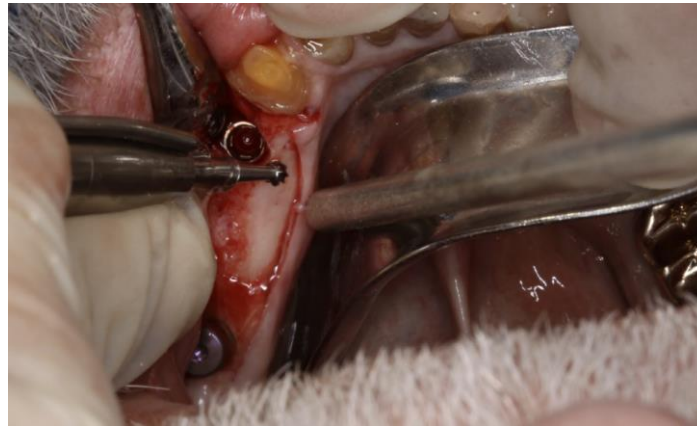


Osteotomies completed

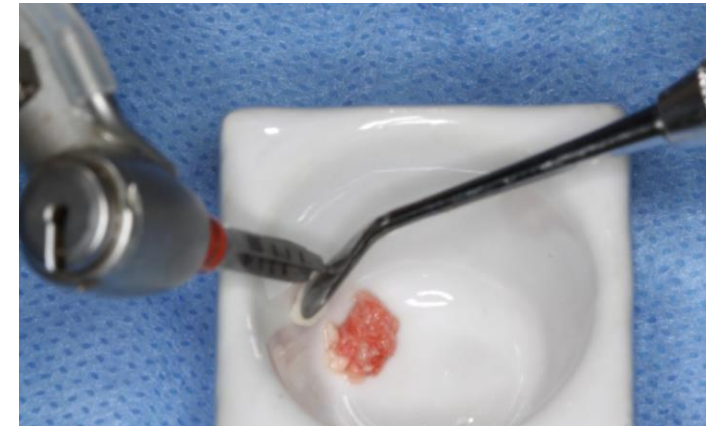Implant Sx cont'd – 4/7/2021



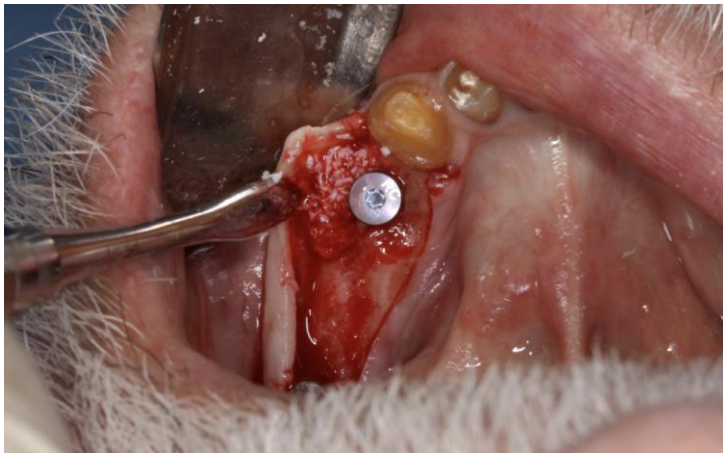Implant placement



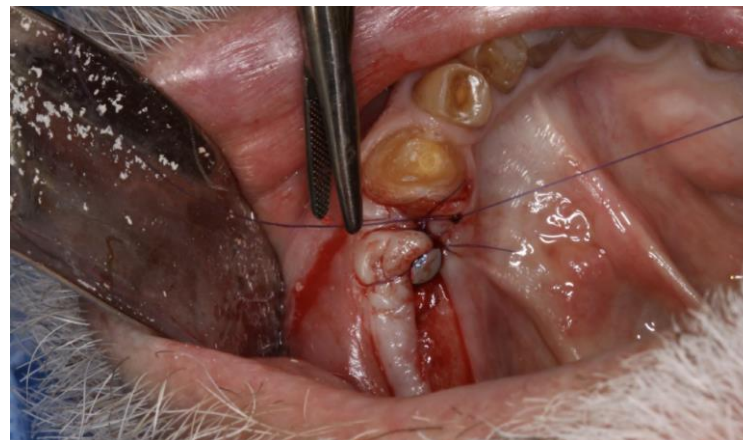
Lingual bone remodeling



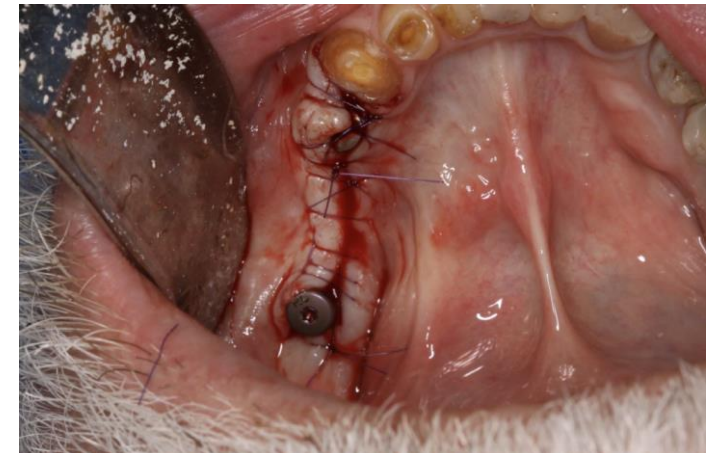Autogenous bone harvesting



Harvested bone placed

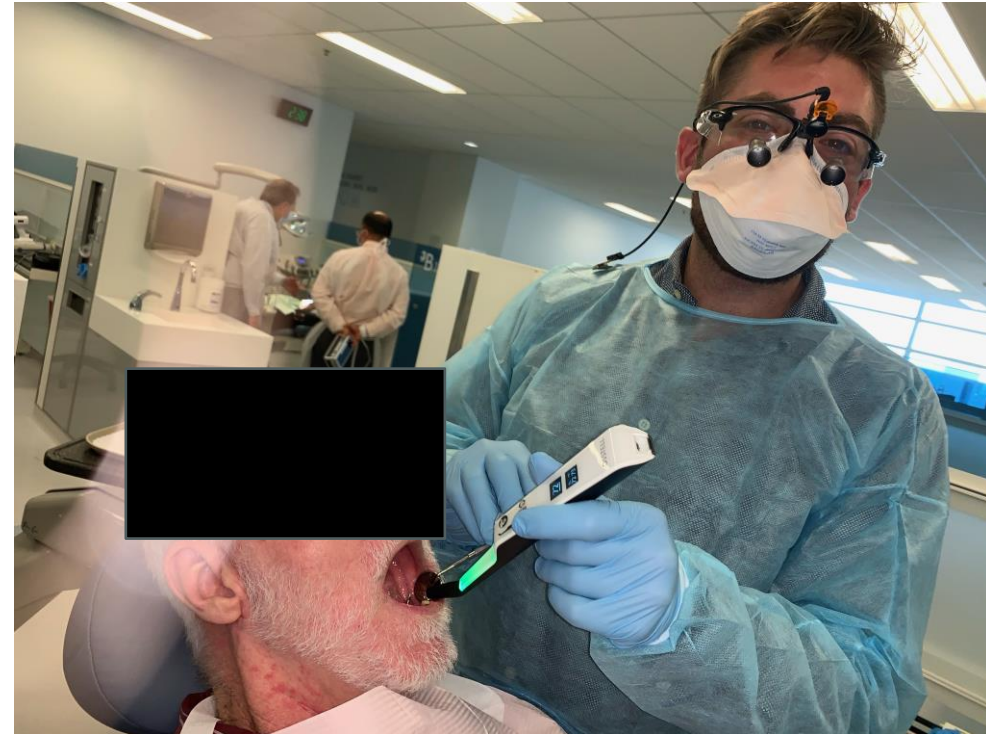
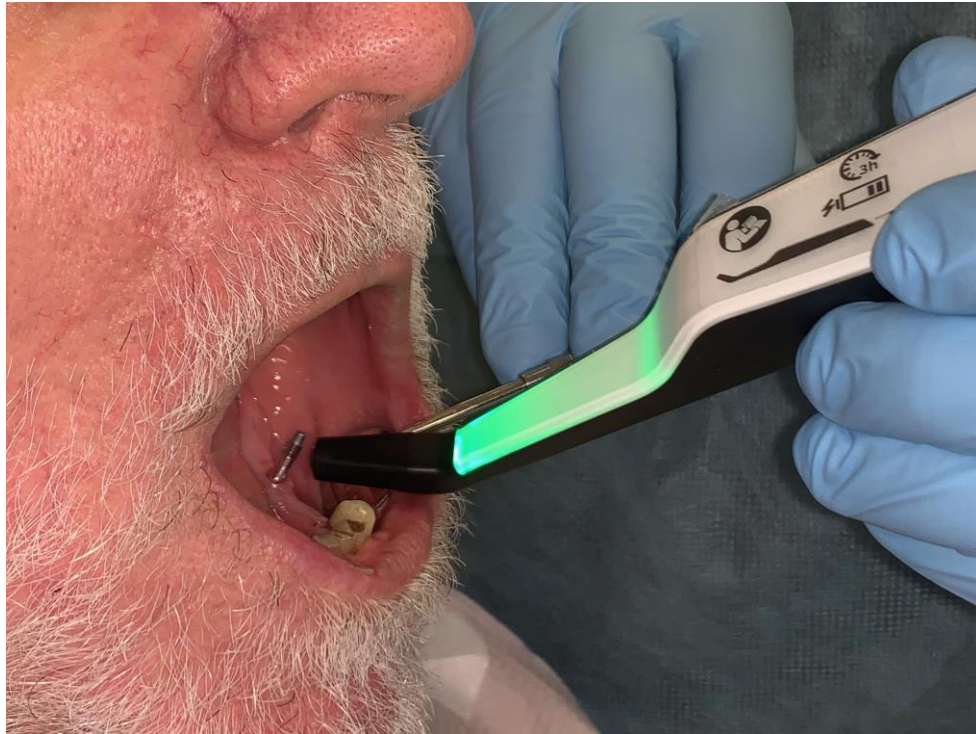
2 collagen membranes over bone



5-0 PGA sutures for 1° closure

Osseointegration Check – 5/13/21



- Used Osstell Beacon to measure implant stability
- Determined to be 73 ISQ (>70 is deemed high stability)⁵
- Digital final impression taken of both implants and #22 crown prep, to be milled with monolithic zirconia

References

1. Chitumalla R, Halini Kumari KV, Mohapatra A, Parihar AS, Anand KS, Katragadda P. Assessment of Survival Rate of Dental Implants in Patients with Bruxism: A 5-year Retrospective Study. *Contemp Clin Dent*. 2018;9(Suppl 2):S278-S282. doi:10.4103/ccd.ccd_258_18
2. Lee JB, Kim MY, Kim CS, Kim YT. The prognosis of splinted restoration of the most-distal implants in the posterior region. *J Adv Prosthodont*. 2016;8(6):494-503. doi:10.4047/jap.2016.8.6.494
3. Vigolo P, Mutinelli S, Zaccaria M, Stellini E. Clinical evaluation of marginal bone level change around multiple adjacent implants restored with splinted and nonsplinted restorations: a 10-year randomized controlled trial. *Int J Oral Maxillofac Implants*. 2015 Mar-Apr;30(2):411-8. doi: 10.11607/jomi.3837. PMID: 2583040
4. Chrcanovic BR, Albrektsson T, Wennerberg A. Bruxism and Dental Implants: A Meta-Analysis. *Implant Dent*. 2015 Oct;24(5):505-16. doi: 10.1097/ID.0000000000000298. PMID: 26218253.
5. H H, G W, E H. The clinical significance of implant stability quotient (ISQ) measurements: A literature review. *J Oral Biol Craniofac Res*. 2020 Oct-Dec;10(4):629-638. doi: 10.1016/j.jobcr.2020.07.004. Epub 2020 Aug 14. PMID: 32983857; PMCID: PMC7494467.