

Jeongsik (Arthur) Oh<sup>1</sup>, Jacqui Payne<sup>1</sup>, Joorok Park<sup>1</sup>, Heesoo Oh<sup>1</sup>

Department of Orthodontics, University of the Pacific, Arthur A. Dugoni School of Dentistry

## Introduction

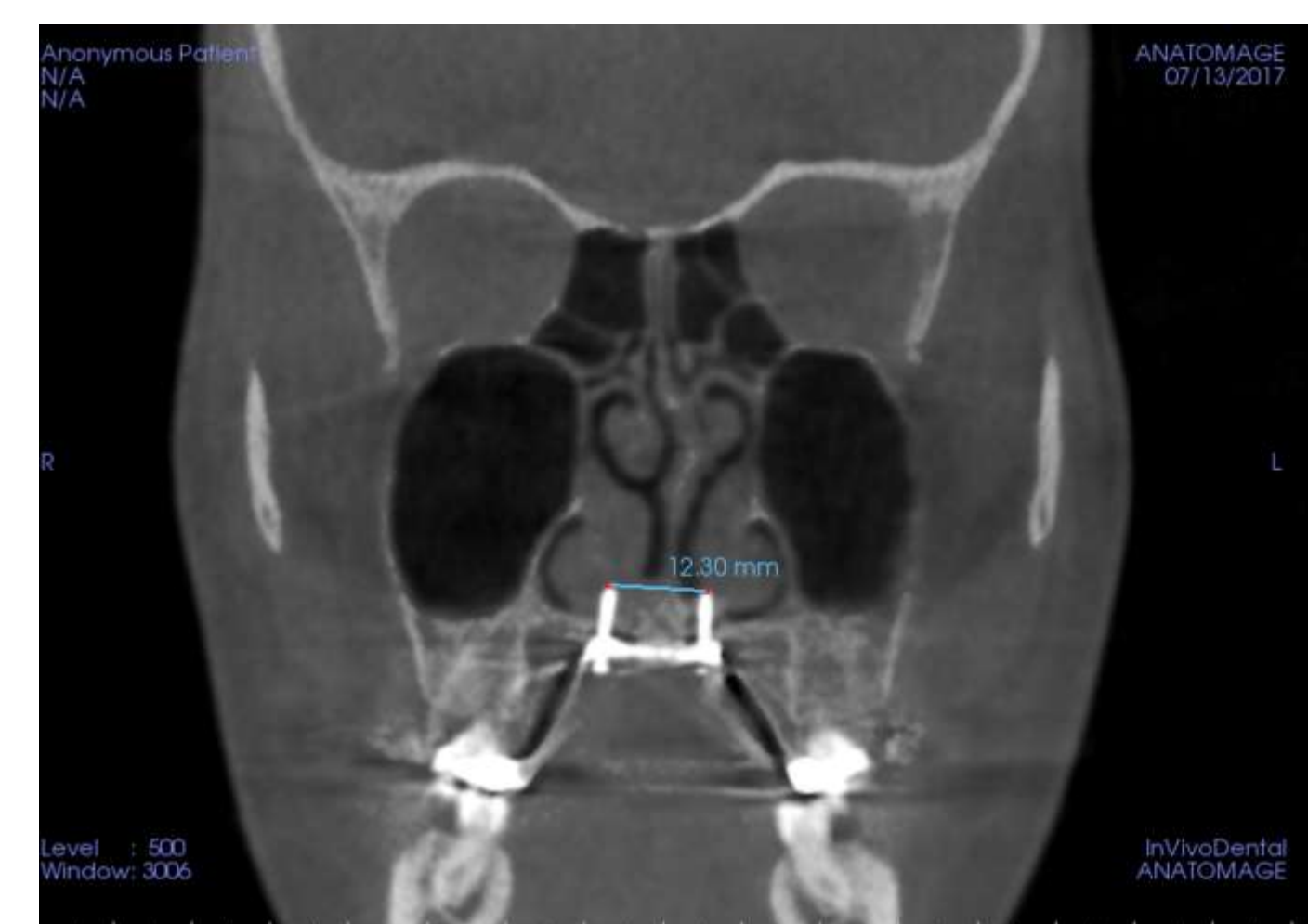
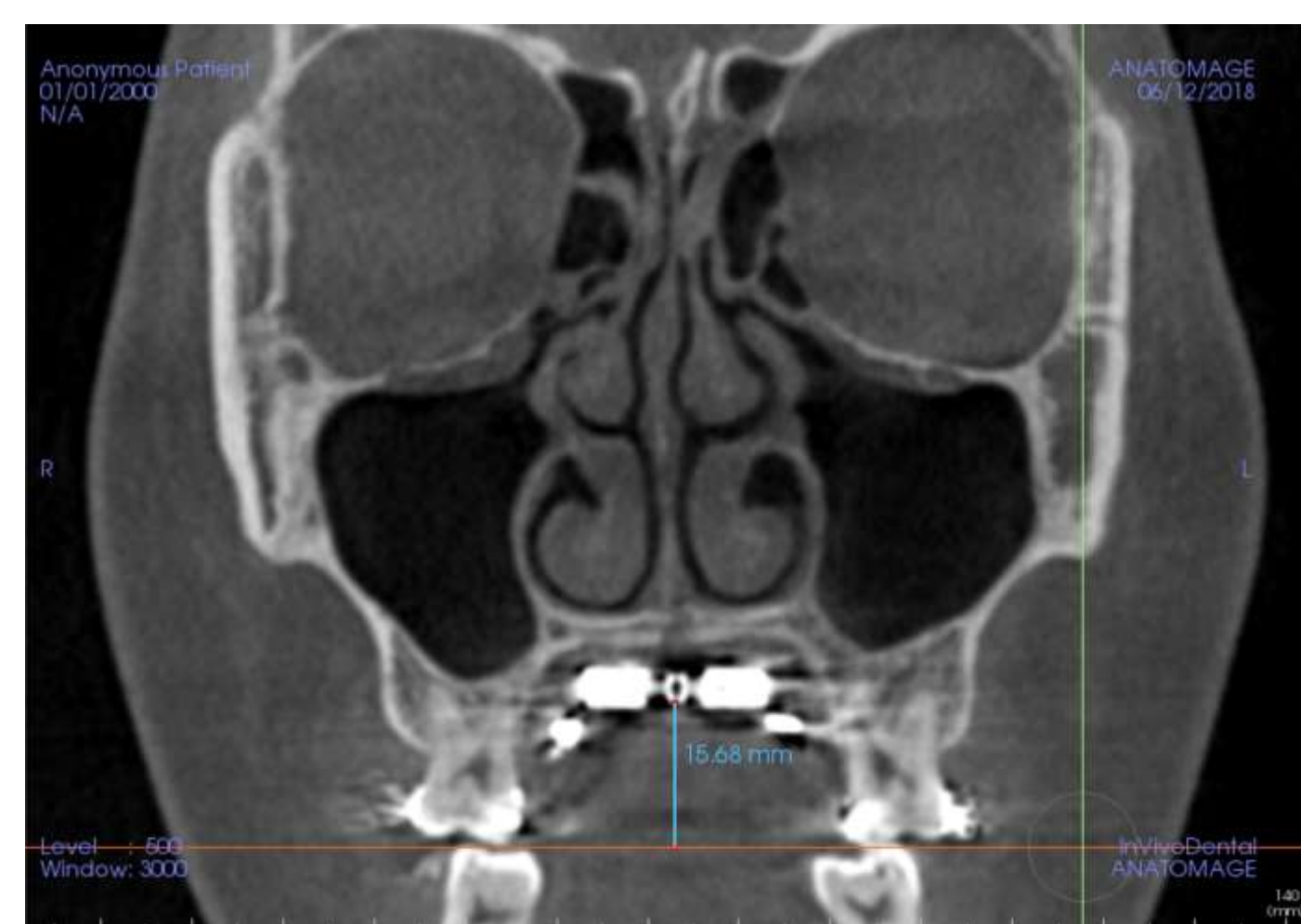
- Maxillary transverse deficiency is a common problem affecting patients within various individual characteristics, and it can be indicated for patients with skeletal Class I, Class II, and Class III malocclusion<sup>1</sup>.
- When palatal expansion becomes a treatment method to correct maxillary transverse deficiency, it is well known that the expansion affects both dental and skeletal components<sup>1</sup>.
- In order to avoid undesired dentoalveolar changes, or when conventional expander can not produce skeletal expansion in young adults due to closure of mid-palatal suture, maxillary expanders anchored micro-implants have been proposed. Studies showed that micro-implants in the palate are efficient and safe support in terms of anchorage and success rate<sup>1</sup>.
- Three-dimensional (3D) computed tomography (CT) provides clinicians and researchers an exact quantitative evaluation of bone and soft tissue changes<sup>2</sup>.

## Objectives

- The purpose of this research is to evaluate amount of dental tipping after MARPE expansion and see if dental tipping correlates to palatal thickness, age, amount of expansion, height from occlusal plane.

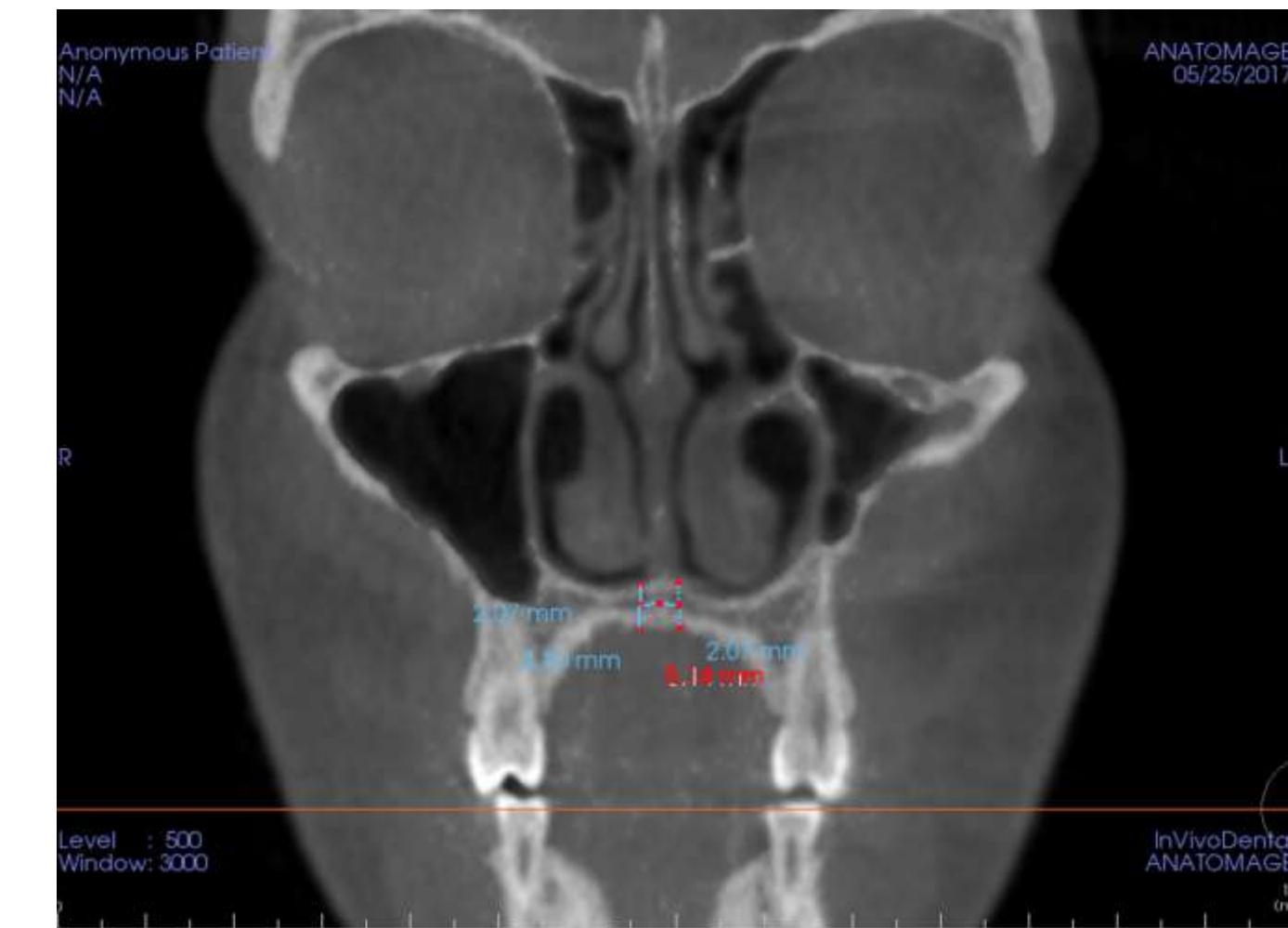
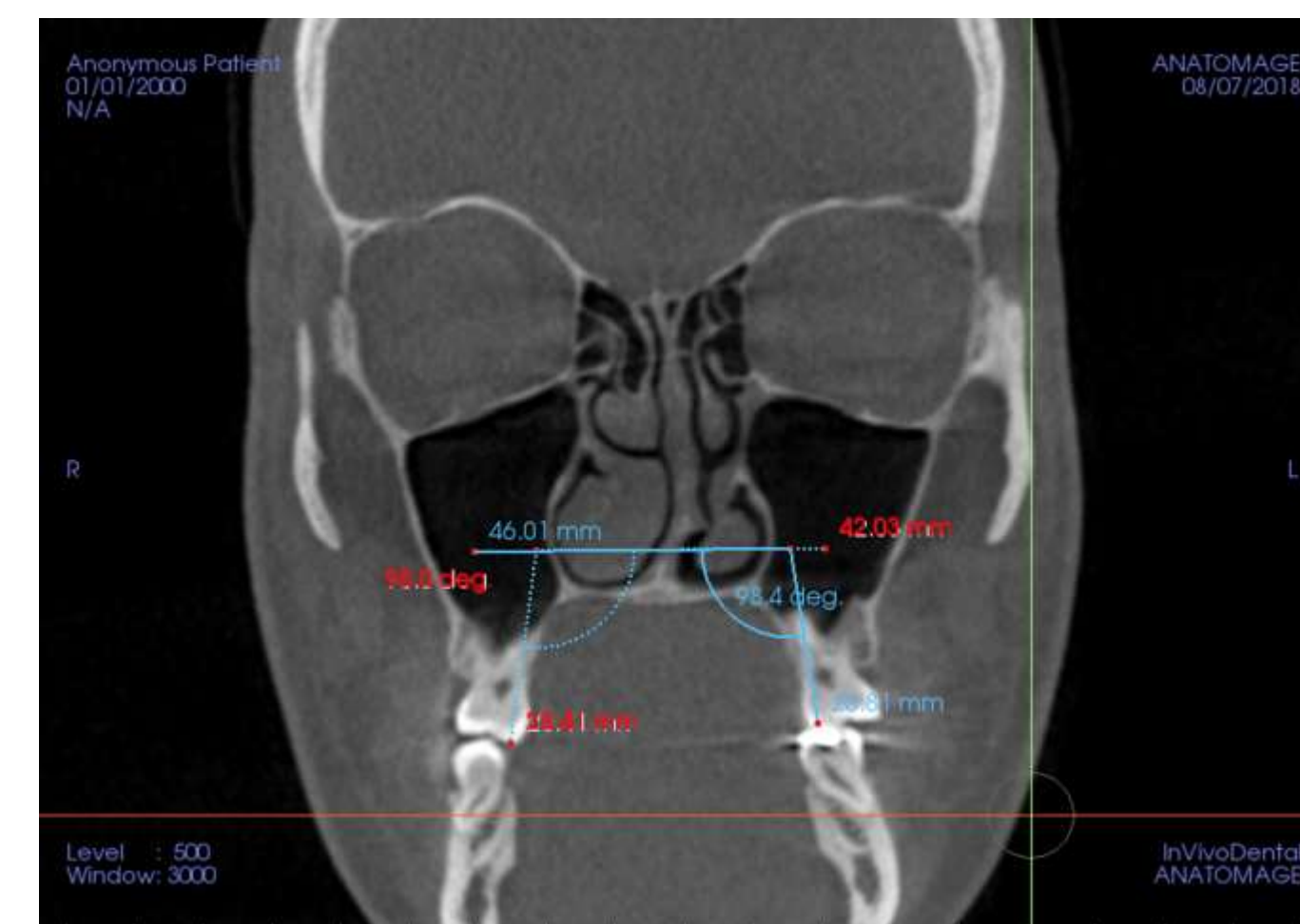
## Material and Methods

- Patients who had undergone MARPE and cone-beam computed tomography at initial (T1) and after expansion (T2) were included in this retrospective study. (n=71)
- 3D tracings and measurements were done by two judges using Invivo 6.
- Changes in the right and left maxillary first molar inclinations (U6 to palatal plane angle) were evaluated with paired t-tests.
- Pearson correlation was used to assess correlation between maxillary first molar inclination change and the following measurements: palatal thickness, age, amount of expansion, and height of jackscrew from occlusal plane.



- Height of jackscrew from occlusal plane was measured from the most inferior portion of the MSE to the occlusal plane of U6.

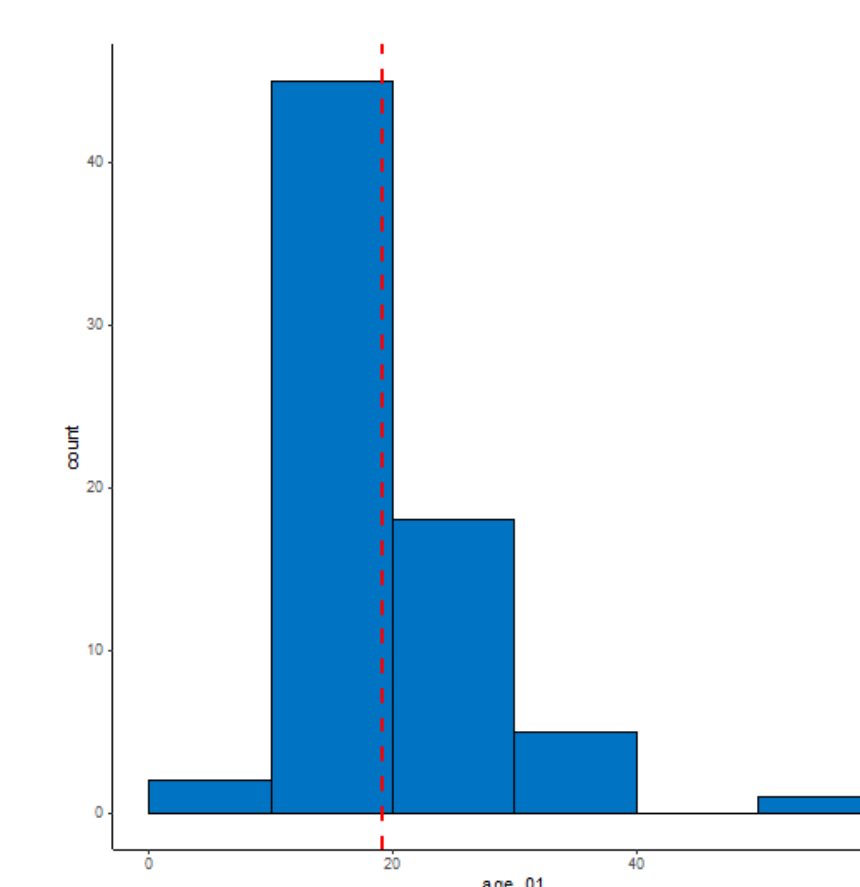
- Distance between posterior screws were measured from the apical most tips.
- Distance between screws at treatment start is 4mm.



- Coronal slice was oriented around the midpoint of the palatal root where both the lingual cusp and the apex of the palatal root could be visualized.
- Molar inclination was measured from lingual cusp tip of U6 through the apex and parallel to the hard palate.
- Within the coronal slice oriented between the maxillary bicuspids, the palatal thickness was measured (2 mm right and left of the mid-palatal suture) from the inferior cortical border to the superior cortical border.

## Results and Discussions

age	Count	Percent (%)
age < 10	2	2.8
10 < age < 20	45	63.4
20 < age < 30	18	25.4
30 < age < 40	5	7
40 < age < 50	0	0
50 < age < 60	1	1.4



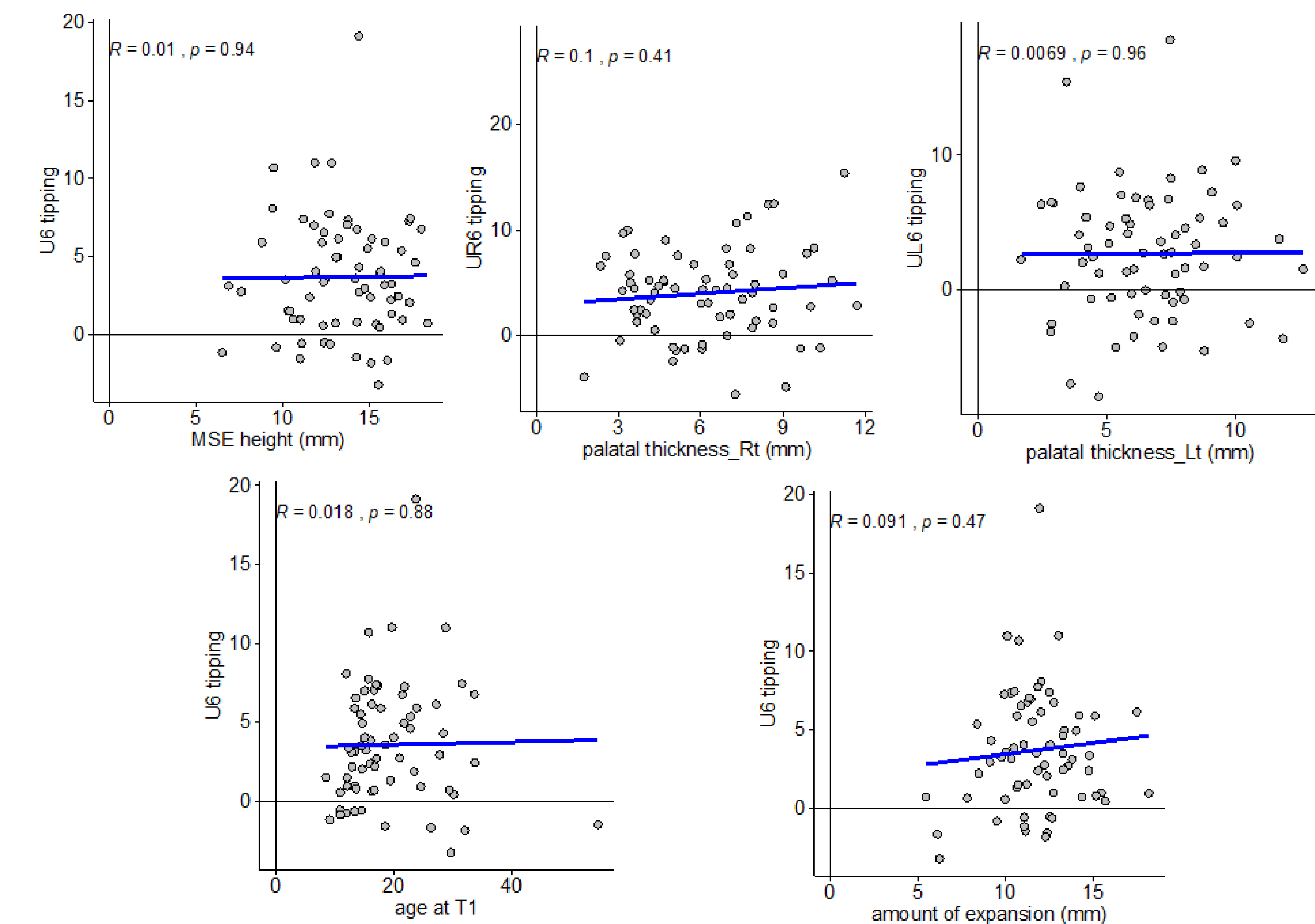
- Average age of patients who have undergone MARPE expansion was 19.1 years old (n=71).
- Average age is represented by red line

	T1	T2	T2-T1	p-value
U6_PP_R	99.7 ± 6.74	104.01 ± 7.05	4.36 ± 5.06	<.0001
U6_PP_L	99.05 ± 6.05	101.72 ± 6.48	2.77 ± 4.77	<.0001
U6_PP	99.37 ± 5.14	102.86 ± 5.2	3.57 ± 3.76	<.0001

- Average amount of dental tipping at T1 and T2.

age at T1	19.07 ± 7.61
age at T2	19.47 ± 7.63
PT_R	6.19 ± 2.4
PT_L	6.51 ± 2.37
PT	6.35 ± 2.35
post_screws_dist	11.75 ± 2.39
OP_MSE_ht	13.51 ± 2.75

- Average palatal thickness, amount of expansion, and height of jackscrew from occlusal plane (measured in mm).
- Data are presented as mean ± standard deviation.



- After MARPE, palatal expansion of  $7.75 \pm 2.39$  mm was achieved
- Maxillary molars (U6) exhibited  $3.57 \pm 3.76^\circ$  buccal tipping.
- Molar inclination from T1 to T2 was statistically significant ( $p < .0001$ ).
- When compared to other study of MSE and dental tipping, similar molar inclination change was observed<sup>3</sup>.
- $3.5^\circ$  molar inclination was seen in our measurements, and  $2.778^\circ$  right and  $2.038^\circ$  left molar inclination was observed in study of Moon et.al<sup>3</sup>.
- Palatal thickness, age, amount of expansion, and height of jackscrew from occlusal plane did not show statistically significant linear correlation with maxillary first molar inclination change.

## Conclusion

- The use of MARPE expansion was effective in generating a palatal widening in both growing and young adult patients
- MARPE appliances can be used to correct transverse maxillary deficiency in adolescent to adult patients with minimal dentoalveolar side effects.

## References

1. Annarumma F, Posadino M, De Mari A, et al. Skeletal and dental changes after maxillary expansion with a bone-borne appliance in young and late adolescent patients. *Am J Orthod Dentofacial Orthop.* 2021;159(4):e363-e375. doi:10.1016/j.ajodo.2020.11.031
2. Landes CA, Laudemann K, Schübel F, et al. Comparison of tooth- and bone-borne devices in surgically assisted rapid maxillary expansion by three-dimensional computed tomography monitoring: transverse dental and skeletal maxillary expansion, segmental inclination, dental tipping, and vestibular bone resorption. *J Craniofac Surg.* 2009;20(4):1132-1141. doi:10.1097/scs.0b013e3181abb430
3. Moon HW, Kim MJ, Ahn HW, et al. Molar inclination and surrounding alveolar bone change relative to the design of bone-borne maxillary expanders: A CBCT study. *Angle Orthod.* 2020;90(1):13-22. doi:10.2319/050619-316.1